

## SPECIAL ARTICLE

# Difficult Airway Society guidelines for management of the unanticipated difficult intubation

J. J. Henderson,<sup>1</sup> M. T. Popat,<sup>2</sup> I. P. Latto<sup>3</sup> and A. C. Pearce<sup>4</sup>

*1 Anaesthetic Department, Gartnavel General Hospital, 1053 Great Western Road, Glasgow G12 0YN, UK*

*2 Nuffield Department of Anaesthetics, John Radcliffe Hospital, Headington, Oxford OX3 9 DU, UK*

*3 Anaesthetic Department, University Hospital of Wales, Heath Park, Cardiff CF14 4XW, UK*

*4 Anaesthetic Department, Guy's Hospital, London SE1 9RT, UK*

### Summary

Problems with tracheal intubation are infrequent but are the most common cause of anaesthetic death or brain damage. The clinical situation is not always managed well. The Difficult Airway Society (DAS) has developed guidelines for management of the unanticipated difficult tracheal intubation in the non-obstetric adult patient without upper airway obstruction. These guidelines have been developed by consensus and are based on evidence and experience. We have produced flow-charts for three scenarios: routine induction; rapid sequence induction; and failed intubation, increasing hypoxaemia and difficult ventilation in the paralysed, anaesthetised patient. The flow-charts are simple, clear and definitive. They can be fully implemented only when the necessary equipment and training are available. The guidelines received overwhelming support from the membership of the DAS.

*Disclaimer:* It is not intended that these guidelines should constitute a minimum standard of practice, nor are they to be regarded as a substitute for good clinical judgement.

**Keywords** *Intubation, intratracheal. Practice guidelines. Cricothyroidotomy. Laryngeal mask airway.*

---

*Correspondence to: John Henderson*

*E-mail: john.henderson@dial.pipex.com*

*\*The guidelines and algorithms were presented in part at annual Difficult Airway Society meetings (DAS). A version of the algorithm has been displayed on the DAS website – <http://www.das.uk.com> since March 2004.*

*Accepted: 11 March 2004*

Problems with tracheal intubation were the most frequent causes of anaesthetic death in the published analyses of records of the UK medical defence societies [1, 2]. The true number is likely to be substantially greater than those published.

Most cases of unanticipated difficult intubation are managed satisfactorily, but problems with tracheal intubation can cause serious soft tissue damage [3] and are the principal cause of hypoxaemic anaesthetic death and brain damage [1, 2, 4]. Management of the unanticipated difficult tracheal intubation must therefore concentrate on maintenance of oxygenation and prevention of airway trauma.

Guidelines for management of the difficult airway have been published recently by North American [5, 6], French [7], Canadian [8] and Italian [9] national societies or groups. A limitation of the American guidelines is the use of flow-charts which allow a wide choice of techniques at each stage. This wide choice makes them less useful for management of airway emergencies than simple and definitive flow-charts such as those in the European [10, 11] or American Heart Association [12] Advanced Life Support guidelines.

In the UK there are no national guidelines for management of unanticipated difficult intubation in the non-obstetric patient. The Royal College of Anaesthetists

has encouraged individual departments to display national guidelines for management of a number of emergencies. In the case of failed intubation and ventilation they suggest that guidelines are developed locally. However, general concern has been expressed about the quality of local guidelines [13, 14].

The Difficult Airway Society (DAS) has developed guidelines for management of the unanticipated difficult intubation in an adult non-obstetric patient. The purpose of this article is to present these guidelines, to justify the choice of techniques, and to discuss alternative management strategies. Paediatric and obstetric patients, and patients with upper airway obstruction, are excluded.

## Methods

The need for airway guidelines was first discussed at the Annual Scientific Meeting of DAS in 1999. The following year, members of DAS considered a structured approach to airway guidelines and initiated development of such guidelines for the management of unanticipated difficult intubation. The aim was to produce simple, clear and definitive guidelines, similar in structure to those of the Advanced Life Support groups. Such guidelines could be used in training drills and could be followed easily in an emergency situation. Definitive guidelines imply the use of recommended techniques at every stage. These techniques must be of proven value and relatively easy to learn.

A prototype flow-chart was presented at the DAS Annual Scientific Meeting in November 2000. There was debate and criticism, and constructive suggestions were received at the meeting and subsequently by electronic mail. The DAS executive committee examined the flow-charts in detail at several meetings. Development was based on evidence, experience and consensus. The published literature on difficult and failed tracheal intubation was reviewed with extensive Medline searches and use of personal bibliographies. Advice was sought from members who had particular expertise or knowledge. Revised flow-charts were presented at the DAS Annual Scientific Meetings in November 2001 and 2002. There was overwhelming support for the concept and content of the flow-charts. A late version of the paper was sent for comments to 27 DAS members who had been particularly involved in the guidelines discussions. Their comments were considered during preparation of the final version.

These guidelines are concerned primarily with difficulty with tracheal intubation when the larynx cannot be seen with conventional direct laryngoscopy. Even when the larynx can be visualised, it is sometimes difficult to pass the tracheal tube. Use of optimum shape of the tracheal tube, with [15–19] or without [20] a stylet,

or passage of an introducer ('bougie') under vision ('visual bougie' technique) with subsequent 'railroading' of the tube into the trachea, are recommended [21].

## The Difficult Airway Society guidelines

The essence of the DAS guidelines for management of unanticipated difficult tracheal intubation is a series of flow-charts. They should be used in conjunction with this paper.

The DAS flow-charts are based on a series of plans. The philosophy of having a series of plans is well established in airway management as no single technique is always effective [22, 23]. Effective airway management requires careful planning so that back up plans (plan B, C, D) can be executed when the primary technique (plan A) fails. This philosophy forms the basis of the DAS guidelines. It is hoped that anaesthetists will always make back up plans *before* performing primary techniques so that adequate expertise, equipment and assistance are available.

Two other principles are particularly important. Maintenance of oxygenation takes priority over everything else during the execution of each plan. Anaesthetists should seek the best assistance available as soon as difficulty with laryngoscopy is experienced.

The basic structure of the DAS flow-charts is shown in Fig. 1. This contains the plans and core techniques, and shows the possible outcomes. The plans are labelled A–D:

**Plan A** Initial tracheal intubation plan.

**Plan B** Secondary tracheal intubation plan, when Plan A has failed.

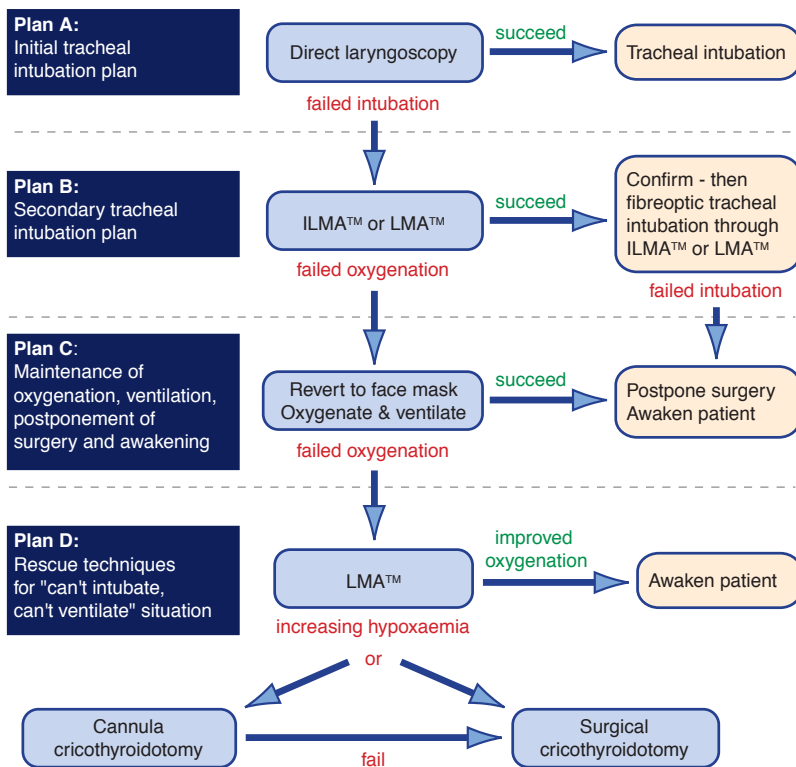
**Plan C** Maintenance of oxygenation and ventilation, postponement of surgery, and awakening the patient, when earlier plans fail.

**Plan D** Rescue techniques for 'can't intubate, can't ventilate' (CICV) situation.

Not all these plans are appropriate to every possible scenario (*vide infra*). The outcome of each plan determines progress to subsequent plans. In some situations, progress depends upon clinical factors, such as the best view of the larynx. Subdivision [24] of the Cormack & Lehane [25] grade 3 into 3a (epiglottis can be lifted) and 3b (epiglottis cannot be lifted from the posterior pharyngeal wall) has a significant effect on the success of the introducer (bougie) [24] and fiberoptic techniques [26].

It was not possible to develop a single detailed flow-chart to cover all clinical scenarios. Detailed flow-charts have therefore been developed for each of the following:

- 1 Unanticipated difficult tracheal intubation – during routine induction of anaesthesia in an adult patient.
- 2 Unanticipated difficult tracheal intubation – during rapid sequence induction of anaesthesia (with succinylcholine) in a non-obstetric patient.



**Figure 1** Basic structure of DAS Guidelines flow-chart.

**3** Failed intubation, increasing hypoxaemia, and difficult ventilation in the paralysed, anaesthetised patient, the ‘can’t intubate, can’t ventilate’ situation.

The principal points of these plans are discussed in more detail. Practical details of some techniques are outlined, but full descriptions should be sought in the references and textbooks. The techniques should be practised under supervision in elective situations, where appropriate, and in manikins.

**Scenario 1: Unanticipated difficult tracheal intubation – during routine induction of anaesthesia in an adult patient (Fig. 2)**

This is the clinical scenario of difficult intubation in an adult patient after induction of general anaesthesia and muscle paralysis, usually with a non-depolarising neuro-muscular blocking drug.

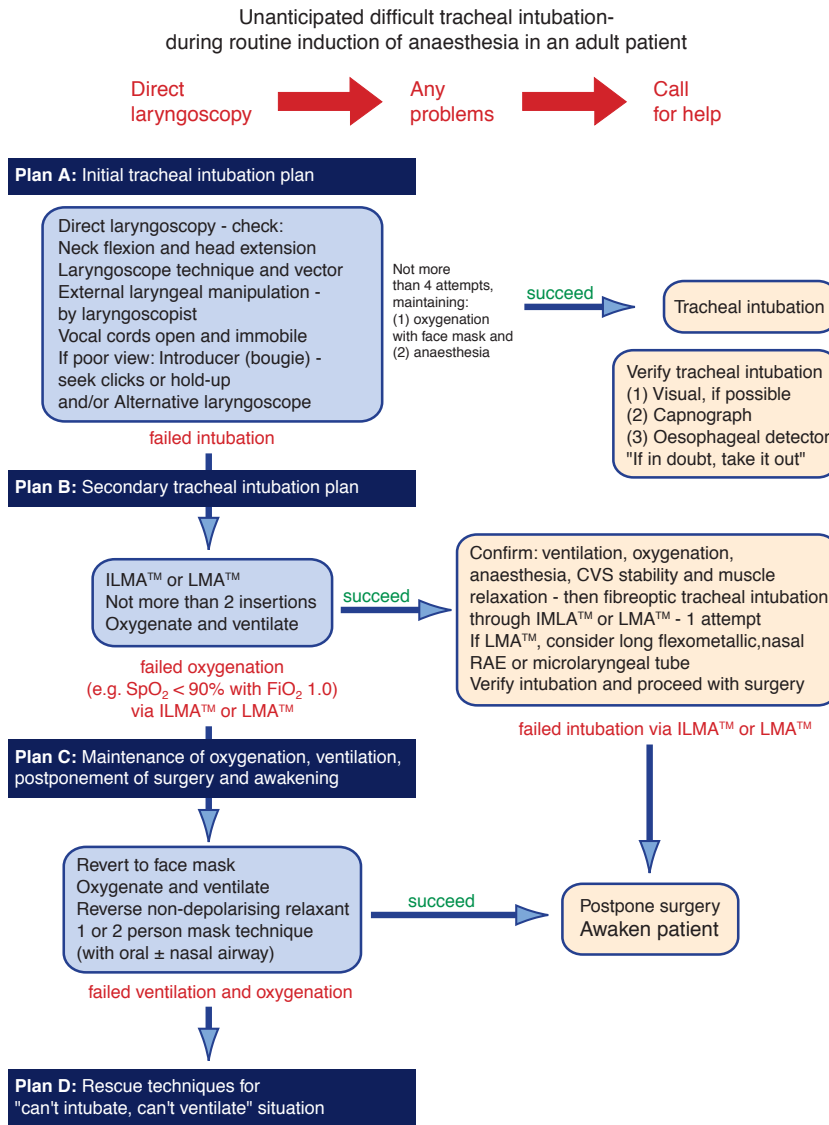
*Plan A: Initial tracheal intubation plan*

The first attempt at direct laryngoscopy should always be performed in optimal conditions after ensuring adequate muscle relaxation and appropriate position of the head and neck (normally the ‘sniffing’ position of head extension and neck flexion) [27]. Use of optimum external laryngeal manipulation (OELM) [28–32] or BURP (backward, upward, and rightward pressure on the thyroid cartilage) [33–35], if required, applied with

the anaesthetist’s right hand, should be an integral part of this first attempt [27]. If, despite these measures, there is still a grade 3 or 4 [25] view, then alternative techniques will be needed. These techniques include use of an introducer (‘gum elastic bougie’) [21] and/or a different laryngoscope. Alternative direct laryngoscopes of proven value include the McCoy [36–40] and straight [41, 42] laryngoscopes. The choice of technique depends upon the experience of the anaesthetist with a particular technique. Oxygenation is maintained with mask ventilation between intubation attempts.

The Eschmann tracheal tube introducer (‘gum elastic bougie’) was designed for multiple use and was marketed in the UK in the early 1970s [43]. It differs from previous introducers in its greater length (60 cm), angled tip and the combination of flexibility and malleability. It is inexpensive and readily available and the technique combines simplicity of operation with a high success rate. It is passed blindly into the trachea when the laryngeal inlet is not visible. The most widely used technique in the UK is the combination of the multiple-use bougie (introducer) with the Macintosh laryngoscope [44]. There is evidence that the bougie is more effective than the stylet when the best view of the larynx is grade 3 [45].

The bougie technique should be used in an optimal way. The Macintosh laryngoscope is left in the mouth



Difficult Airway Society Guidelines Flow-chart 2004 (use with DAS guidelines paper)

**Figure 2** Management of unanticipated difficult tracheal intubation – during routine induction of anaesthesia in an adult patient.

and attempts are made to insert the bougie blindly into the trachea. It is important to maximise the chance of the bougie entering the trachea. The anaesthetist will not see the bougie entering the larynx when the laryngoscopy view is grade 3 or 4. Therefore it is important to be able to recognise whether the bougie is in the trachea or the oesophagus. Clicks can often be felt by the anaesthetist when the bougie is passed into the trachea [46–48]. These are caused by the tip of the bougie hitting the tracheal cartilages. Clicks are more likely to be elicited if the distal end of the bougie is bent into a curve of about 60° [49]. If clicks are present, proceed with intubation by passing (‘railroading’) the tube over the bougie (*vide infra*). Clicks will not be present if the bougie goes down the centre of the

tracheal lumen or is in the oesophagus. If clicks are not elicited, the bougie should be advanced gently to a maximum distance of 45 cm. If distal hold-up is sensed as slight resistance to further advancement, indicating that the bougie is held up in the bronchial tree, proceed with intubation [47]. If the patient is not fully paralysed, coughing may indicate the presence of the bougie in the trachea [46]. If neither clicks, hold-up nor coughing are elicited, the bougie is probably in the oesophagus. Remove the bougie and consider another attempt at passing the bougie blindly into the trachea – if the laryngeal view is 3a [47].

Once the bougie is in the trachea, the tracheal tube is railroaded over the bougie. Railroading is facilitated if the laryngoscope is kept in the mouth [50] and the tube is

rotated 90° anticlockwise [50, 51]. Use of a small tube [52–54], reinforced tube [55, 56], the tube (Euromedical ILM) supplied with the Intubating Laryngeal Mask [57, 58] and the Parker tube [59] have all facilitated railroading in flexible fiberoptic intubation. By analogy, it is probable that these tube factors will facilitate railroading with the Eschmann introducer.

Success rates with the original reusable Eschmann introducer in prospective studies have varied between 94.3% [24], 99.5% [48] and 100% [49]. Optimum results depend on regular use and experience [48]. However, the technique is of limited value when it is not possible to elevate (grade 3b) [24] or visualise (grade 4) [25] the epiglottis. There are concerns that some recently introduced single-use disposable introducers are not as effective as and may cause more trauma than the original multiple-use bougie [60–62].

Alternative techniques of laryngoscopy, of proven value, may be used by those experienced in these techniques. In particular there is considerable evidence of the value of the following techniques in experienced hands:

- direct use of the flexible fiberoptic laryngoscope [63, 64];
- Bullard-type laryngoscope [65–75].

There are situations in which these techniques can offer unique advantages. The lighted stylet is not a visual technique, but may be successful in experienced hands [76].

Multiple and prolonged attempts at laryngoscopy and tracheal intubation are associated with morbidity [77–81] and mortality [3, 77, 78, 82]. The extent of laryngeal oedema may not become apparent until fiberoptic examination [83] or extubation [84]. An essential component of Plan A is therefore to limit the number and duration of attempts at laryngoscopy in order to prevent trauma and development of a ‘can’t ventilate’ situation. It is difficult to justify use of the same direct laryngoscope more than twice and the maximum number of laryngoscope insertions should be limited to four. However, tracheal intubation may be successful when it is performed by a more experienced anaesthetist and one such additional attempt is worthwhile [85, 86].

When these attempts at tracheal intubation have been unsuccessful, Plan B should be implemented.

#### *Plan B: Secondary tracheal intubation plan*

A different approach is required when direct laryngoscopy has failed. Alternative techniques can allow continuous ventilation and oxygenation both *during* and *between* intubation attempts. This is best achieved by using a ‘dedicated airway device’, defined as ‘an upper airway device which maintains airway patency while facilitating tracheal intubation’ [87]. Although the classic laryngeal

mask airway (LMA<sup>TM</sup>) has been recommended as a ventilation and intubation device in patients with a difficult airway [88], it was not designed as a conduit for tracheal intubation and has clear limitations when used for this purpose (*vide infra*). Any other supraglottic airway device could be used, but the intubating laryngeal mask (ILMA<sup>TM</sup>) [89, 90] was designed specifically to facilitate tracheal intubation while maintaining ventilation. Each of these devices has advantages and disadvantages.

*ILMA<sup>TM</sup> for secondary tracheal intubation:* Numerous reports have confirmed the effectiveness of the ILMA<sup>TM</sup> for both ventilation and blind intubation in patients *without* airway difficulties [89, 91–98]. The overall intubation success rate in 1100 patients in these studies was 95.7% [90]. Further studies have confirmed its value in management of patients with *known* or *anticipated* difficult tracheal intubation [99–107]. The ILMA<sup>TM</sup> has also proved to be a useful device in the management of *unanticipated* difficult intubation. In one study, blind intubation was performed in 20 out of 23 patients with a 75% success rate at the first attempt (10% required two or three attempts and 5% required four attempts) and 100% overall success rate [104]. Fiberoptic guided intubation was successful at the first attempt in the remaining three patients.

Although high success rates can be achieved with a blind technique, several attempts may be required and the incidence of oesophageal intubation can be up to 5% [108, 109]. Transillumination techniques may improve first-attempt success rates [110] and certainly reduce the number of manoeuvres required, the incidence of oesophageal intubation and the time required to achieve intubation [111, 112]. However, intubation under vision through the ILMA<sup>TM</sup> using a flexible fiberoptic laryngoscope has real advantages. The first-attempt [104] and overall [113] success rates are higher than blind techniques, and it nearly always succeeds when blind intubation fails [103].

The techniques of insertion and intubation through the ILMA<sup>TM</sup> differ in many respects from the classic LMA<sup>TM</sup>, and training and practice are essential if it is to be used to achieve a high success rate and minimise trauma in the unanticipated difficult tracheal intubation. A learning curve of about 20 insertions has been described [95, 114]. The manufacturer’s instruction manual describes the insertion and intubation techniques, the adjustments necessary for ideal positioning of the device and an approach to problem-solving [115]. The ‘Chandy manoeuvre’ (alignment of the internal aperture of ILMA<sup>TM</sup> and the glottic opening by finding the degree of sagittal rotation which produces optimal ventilation, and then applying a slight anterior lift with the ILMA<sup>TM</sup> handle) facilitates correct positioning and blind intubation

through the ILMA™ and has been shown to reduce the number of intubation attempts [104]. Use of the dedicated silicone tracheal tube is strongly recommended [115]. The fibroscope can be used to visualise the ‘Epiglottic Elevator Bar’ lifting the epiglottis and observe passage of the tracheal tube through the glottis [90, 116] or it can be passed into the trachea after glottic visualisation and then used to railroad the tube [104]. We prefer the latter technique. The lubricated silicone tracheal tube is first inserted into the shaft of the ILMA™ until its tip reaches the mask aperture (indicated by the transverse line on the tube). The fibroscope is then inserted through the tracheal tube so that its tip is just within the tip of the tube. The tube and fibroscope are then advanced together for about 1.5 cm so that the ‘Epiglottic Elevator Bar’ is seen to elevate the epiglottis. Once the tip of the tube is in the larynx, the fibroscope is advanced into the trachea and the tube is then railroaded over it [90, 104]. Finally, the position of the tube is checked with the fibroscope during withdrawal. Oxygen and anaesthetic gases can be delivered continuously if a self-sealing bronchoscope connector is attached between the 15-mm tracheal tube connector and the anaesthetic breathing system [104]. Ventilation is maximised by using a wide tracheal tube with a narrow fibroscope [117]. The ILMA™ should be removed when tracheal intubation has been verified and the tracheal tube secured [118, 119].

*Classic LMA™ for secondary tracheal intubation:* Fiberoptic tracheal intubation through the classic LMA™ (the role of the single-use LMA™ in management of the difficult airway patient has not been established) should be considered when an ILMA™ is not available. Although Heath [120] reported a 93% success rate for blind intubation through the LMA™ (in the absence of cricoid pressure), others have achieved much lower success rates [121, 122] and blind intubation cannot be recommended. Success rates of 90–100% (depending on technique, equipment, number of attempts allowed and experience of user) can be achieved with fiberoptic intubation through the classic LMA™ [113, 123, 124]. The limitations of the classic LMA™ as a conduit for intubation are well known [125, 126] and include the following:

- The LMA™ tube connector is narrow and will only allow a 6 mm (ID) tracheal tube through a size 3 or 4 LMA™ and 7 mm (ID) through a size 5 LMA™;
- The LMA™ tube is so long that the cuff of an uncut normal tracheal tube (26–27 cm) may lie between the vocal cords so that it is ineffective and potentially traumatic. A long flexometallic tube [127], nasal RAE [128] or a microlaryngeal tube [129–131] is recommended.

- The mask aperture bars may obstruct the passage of the tracheal tube;
- Manipulation requires head and neck movement and/or finger insertion, both of which may worsen difficulties.

Difficulties may be encountered during subsequent removal of the LMA™. The LMA™ may be left *in situ* if its presence does not interfere with surgical access. Techniques of LMA™ removal without dislodging the tracheal tube have been described, but they may fail and expose the patient to avoidable danger [132].

The problems mentioned above can be avoided by using a two-stage technique with a flexible fiberoptic laryngoscope and an Aintree Intubation Catheter [87, 133, 134].

Whatever technique of tracheal intubation through a ‘dedicated airway’ is used, the vocal cords should be open and non-reactive before attempting to advance the fibroscope or tracheal tube into the trachea. If two attempts at the secondary tracheal intubation technique fail, surgery should be postponed and the patient awakened, i.e. Plan C should be implemented.

*Plan C: Maintenance of oxygenation and ventilation, postponement of surgery and awakening the patient – if Plans A and B have failed*

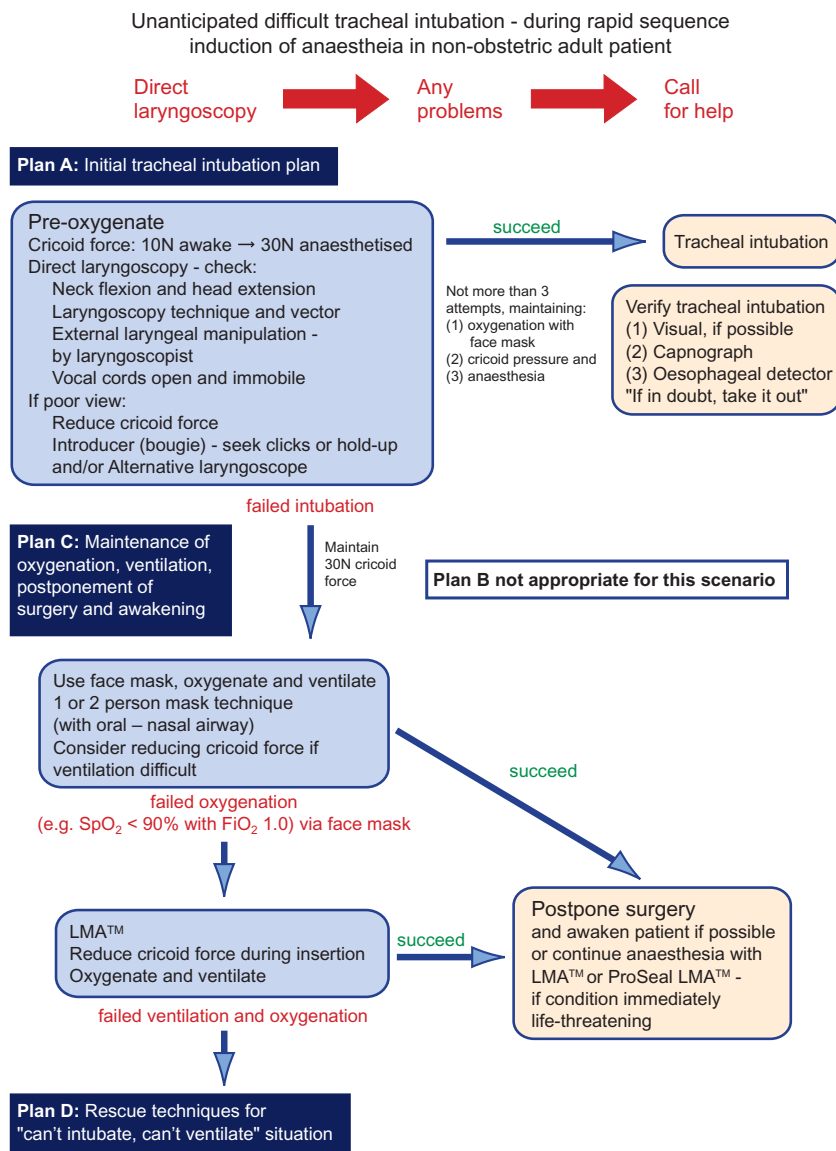
If Plan B (secondary tracheal intubation technique) fails, it remains important to avoid trauma to the airway and to maintain ventilation and oxygenation with the dedicated airway device. Elective surgery should be cancelled and the airway device should be removed only after muscle relaxation has been reversed, spontaneous ventilation is adequate, and the patient is awake. An alternative plan for anaesthesia can then be made. Although it may be possible to perform surgery under regional anaesthesia, the safest plan is to secure the airway with the patient awake [135]. If adequate ventilation and oxygenation cannot be achieved with the dedicated airway device, ventilation should be performed using a face mask with or without an oral or nasal airway.

If ventilation is impossible and serious hypoxaemia is developing, then Plan D (Rescue techniques for ‘can’t intubate, can’t ventilate’ situation) should be implemented without delay (*vide infra*).

### **Scenario 2: Unanticipated difficult tracheal intubation – during rapid sequence induction of anaesthesia (with succinylcholine) in a non-obstetric patient (Fig. 3)**

*Plan A: Initial tracheal intubation plan*

In scenario 2, in contrast to scenario 1, there is an increased likelihood of regurgitation or vomiting, with a



**Figure 3** Management of unanticipated difficult tracheal intubation – during rapid sequence induction of anaesthesia (with succinylcholine) in a non-obstetric patient.

consequent risk of pulmonary aspiration. The change in management involves the use of pre-oxygenation and the application of cricoid pressure. It is particularly important to use a pre-oxygenation technique which maximises oxygen stores [136].

Cricoid pressure has played an important role in the prevention of pulmonary aspiration since its introduction by Sellick [137]. It is an integral part of the flow-chart for the patient having rapid sequence induction. However, it can impair insertion of the laryngoscope [138], passage of an introducer [139] and can cause airway obstruction [140–146]. A force of 30 N provides good airway protection, while minimising the risk of airway obstruction [147], but is not well tolerated by

the conscious patient. Cricoid pressure should be applied with an initial force of 10 N when the patient is awake, increasing to 30 N as consciousness is lost [139]. The force should be reduced, with suction at hand, if it impedes laryngoscopy or causes airway obstruction.

The principles of optimising the initial tracheal intubation technique, and use of the Eschmann introducer and alternative direct laryngoscopes, are the same as in Plan A in the elective patient. If intubation fails despite a maximum of three attempts, a failed intubation plan with the aim of maintaining oxygenation and awakening the patient (Plan C) is initiated immediately. Further doses of succinylcholine should not be given.

*Plan C: Maintenance of oxygenation and ventilation and postponement of surgery, if possible*

Plan B is omitted from airway management of the patient having rapid sequence induction for two reasons. The risk of regurgitation or vomiting is greater than in the elective patient, so that the risk of aspiration during further attempts at tracheal intubation is higher. The short duration of succinylcholine increases the risk of laryngospasm and difficulty with laryngoscopy during recovery of neuromuscular function, so that further tracheal intubation attempts increase the risk to the patient. When initial attempts at tracheal intubation in this scenario fail, the safest plan in most patients is to postpone surgery and awaken the patient.

Plan C of this scenario contains two subsidiary scenarios, in which the urgency of proceeding with surgery differs. A risk-benefit assessment balances the risks of delaying surgery against the risk of proceeding with a suboptimal airway. If it is essential to proceed with surgery, the traditional technique has been to continue with a face mask and oral airway, maintaining cricoid pressure [148, 149]. Continuation of anaesthesia with a classic LMA<sup>TM</sup> is now an established technique [150, 151], although not always effective [152] or accepted [149, 153] (effect of cricoid pressure on LMA<sup>TM</sup> insertion – *vide infra*). If it proves difficult to ventilate the lungs as a consequence of gas leakage past the cuff of the classic LMA<sup>TM</sup>, use of the ProSeal LMA<sup>TM</sup> should be considered. The ProSeal LMA<sup>TM</sup> forms a better seal [154–160] than the classic LMA<sup>TM</sup> and provides improved protection against aspiration [161–164]. The potential advantages of the ProSeal LMA<sup>TM</sup> have to be offset against increased complexity of insertion [157, 160, 165, 166] (not a problem when a precise technique [166] and the insertion tool are used [156, 167]). The risk (about 5%) of airway obstruction [168] may be lower than that with the classic LMA<sup>TM</sup> [158]. Airway obstruction may be overcome by reinsertion [169], use of a smaller size [170], withdrawal of air from the cuff [167, 170] and/or moving the head and neck into the sniffing position [167]. However, poor seal and airway obstruction may be significant problems in some obese patients [171].

Wherever possible the aim should be to postpone surgery and awaken the patient. Maintenance of ventilation and oxygenation with a face mask is a conventional technique. This may include the one- or two-person technique and the use of an oral or nasal airway. A narrow, soft, lubricated nasopharyngeal airway may be inserted gently [172, 173] if this can be done without trauma [174, 175]. It may be necessary to reduce cricoid force in order to achieve satisfactory ventilation. If satisfactory oxygenation (e.g.  $S_pO_2 > 90\%$  with  $F_{iO_2} 1.0$ ) cannot be achieved with a face mask, the LMA<sup>TM</sup>

should be used. Cricoid force impedes positioning of [176–180] and ventilation through [180–183] the LMA<sup>TM</sup>. It may be necessary to reduce cricoid force during LMA<sup>TM</sup> insertion when it is used in an emergency [177, 178].

If ventilation is impossible and serious hypoxaemia is developing, then Plan D (Rescue techniques for ‘can’t intubate, can’t ventilate’ situation) should be implemented without delay.

**Scenario 3: Failed intubation, increasing hypoxaemia and difficult ventilation in the paralysed anaesthetised patient**

*Plan D: Rescue techniques for ‘can’t intubate, can’t ventilate’ situation (Fig. 4)*

This scenario may develop rapidly, but often occurs after repeated unsuccessful attempts at intubation in scenarios 1 and 2, where a ‘can ventilate’ situation develops into a ‘can’t intubate, can’t ventilate’ (CICV) situation [77, 78, 81, 82]. It is probable that most patients who suffer hypoxic damage pass through a CICV stage [77, 184]. In situations where mask ventilation fails to oxygenate the patient, the upper airway is normally sufficiently patent to allow gas to escape upwards [185–189]. This has an important bearing on the efficacy of different airway rescue techniques (*vide infra*).

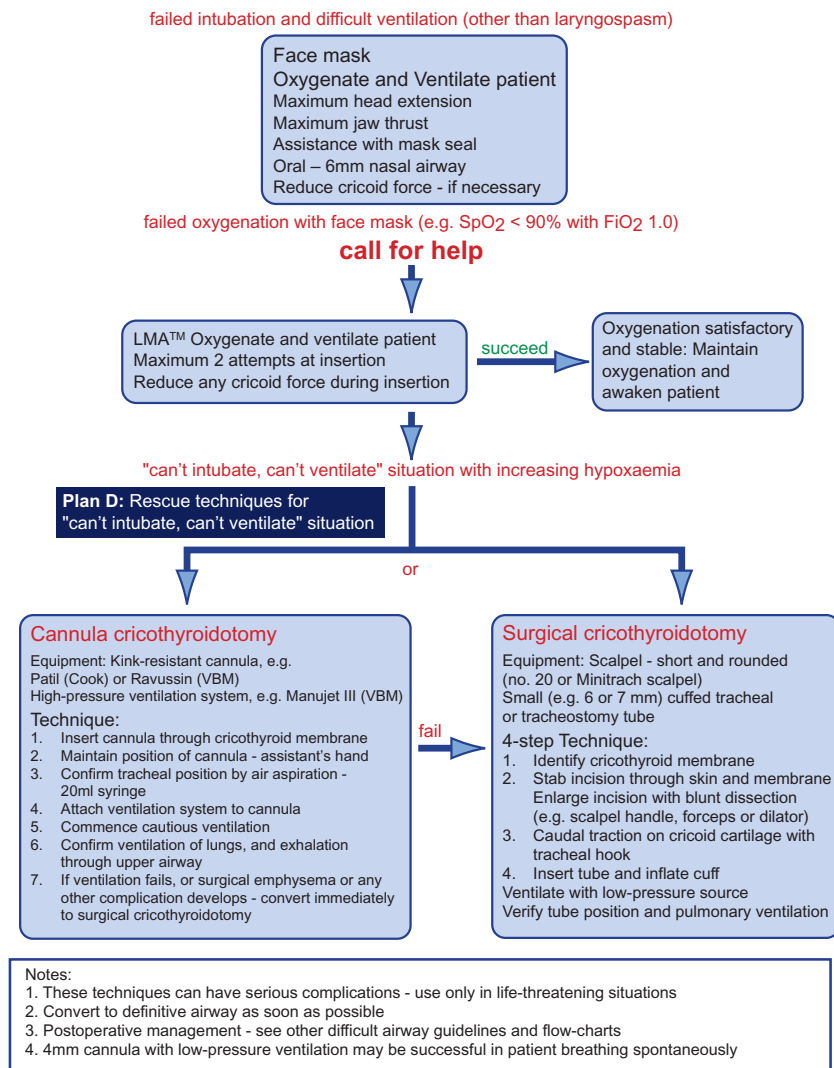
Before resorting to invasive rescue techniques, it is essential that a maximum effort has been made to achieve ventilation and oxygenation with non-invasive techniques, such as optimum mask ventilation and the LMA<sup>TM</sup>.

Other supraglottic airway devices, particularly the Combitube<sup>TM</sup>, have been used in the CICV situation. Satisfactory placement of the Combitube is not always possible, even when inserted with a laryngoscope [190]. When properly positioned, it allows ventilation with a higher seal pressure than the classic LMA<sup>TM</sup>, protects against regurgitation [191], and allows subsequent attempts [192] at intubation while the inflated oesophageal cuff maintains airway protection. Although there have been failures [193, 194], the Combitube has been used successfully in the difficult intubation [191, 195] and the CICV situation [196–199], including failure with the LMA<sup>TM</sup> [200]. Adjustment of cuff pressure may be necessary [201]. The Combitube is a large and bulky device, and there have been some reports of oesophageal damage with the original product [202–205], but the risk should be lower with the SA (Small Adult) size [192, 206]. The decision to use the Combitube will depend on availability, experience and the clinical situation.

The risks of an invasive rescue technique must be constantly weighed against the risks of hypoxic brain



Failed intubation, increasing hypoxaemia and difficult ventilation in the paralysed anaesthetised patient: Rescue techniques for the "can't intubate, can't ventilate" situation



**Figure 4** Management of failed intubation, increasing hypoxaemia and difficult ventilation in the paralysed anaesthetised patient.

Difficult Airway Society guidelines Flow-chart 2004 (use with DAS guidelines paper)

damage or death [207]. Rapid development of severe hypoxaemia, particularly associated with bradycardia, is an indication for imminent intervention with an invasive technique. Once the decision to perform an invasive technique is made, it is essential to use an effective technique. Rapid reoxygenation is now necessary, and this is best achieved with a combination of an invasive airway device and a ventilation technique which is capable of reliably delivering a large minute volume with an  $F_iO_2$  of 1.0. Many cricothyroidotomy techniques have been criticised because they are not capable of providing effective ventilation [4, 208–213].

Classical emergency surgical tracheostomy involves incision through skin and platysma, division of the isthmus of the thyroid gland, haemostasis, incision of tracheal

cartilage, and insertion of a cuffed tracheostomy tube [214]. Emergency tracheostomy can be very difficult and have serious complications [215–217]. A few surgeons may succeed in 3 min [85, 218], but most will take longer [217, 219]. Delay in completion of tracheostomy in this situation results in death of the patient [77, 219–224].

There are a few case reports of successful use of percutaneous tracheostomy techniques in the failed intubation [225–227] and CICV situation [228]. However, percutaneous tracheostomy techniques include a number of steps and can take time.

The anaesthetist must be prepared to use invasive techniques to secure the airway via the cricothyroid membrane. Success depends on understanding the anatomy of the cricothyroid membrane [229–231] and of the

factors which determine efficacy of ventilation with different airway devices.

Invasive airway devices which are frequently recommended include:

- cuffed tracheal or tracheostomy tubes;
- narrow (4–6 mm ID) uncuffed tubes;
- cannulae.

These must be matched to the ventilation technique in order to provide a system which can deliver a large minute volume. When a cuffed tube is used, a low-pressure ventilation system is satisfactory. When a 4-mm (ID) uncuffed tube is used, successful ventilation is less certain [232–235]. The ‘inflated’ gas may enter the lungs or flow out through the upper airway. Factors which promote entry of gas into the lungs include high resistance in the upper airway, high lung compliance, high flow rate and long inflation time. The limitations of uncuffed tubes in the CICV situation are well summarised by Walls [236]. **When a cannula is used, a high-pressure ventilation source is necessary.** This system is discussed clearly by Dworkin [237].

All current airway guidelines [5–8,12] recommend management of the CICV situation using:

- cannula cricothyroidotomy with percutaneous transtracheal jet ventilation (TTJV) or;
- surgical cricothyroidotomy.

They remain the standard techniques.

**Cannula cricothyroidotomy:** Cannula cricothyroidotomy involves the combination of insertion of a cannula through the cricothyroid membrane with high-pressure ventilation. It can provide effective ventilation [4, 209, 238–241], although low success rates have been reported [242]. We recommend use of kink-resistant cannulae because standard intravenous cannulae are easily kinked [243–245]. The technique is summarised in the flow-chart and is described in detail by Benumof [246] and Stewart [247]. Verification of correct cannula placement by aspiration of air into a large syringe, before the use of high-pressure ventilation, is essential. Subsequent dislodgement of the cannula must be prevented.

A high-pressure source is needed to achieve effective ventilation through a cannula. The oxygen flush systems of most modern anaesthesia machines do not provide sufficient pressure [211, 248, 249] and an adjustable high-pressure device (driven by gas pipeline pressure) with a Luer Lock connection is recommended. Barotrauma [188, 238, 250, 251] is less likely if an initial inflation pressure of less than 4 kPa (55 psi) is used [213, 251, 252]. Some have recommended insertion of a second cannula to facilitate exhalation [185, 186, 253]. However, the driving pressure for exhalation is relatively low and use of a second cannula is not a reliable

means of relieving high airway pressure [254, 255]. Initial high-pressure ventilation should be performed particularly cautiously. It is important to keep the upper airway as open as possible and to verify deflation of the lungs and exhalation through the upper airway. If an LMA has been used, it should be kept in place to facilitate exhalation.

**Surgical cricothyroidotomy:** Surgical (‘stab’) cricothyroidotomy can allow rapid restoration of ventilation and oxygenation in the CICV situation [77, 242, 256–260] and is included in ATLS and military [261] training. Anaesthetic deaths could be prevented by appropriate use of surgical cricothyroidotomy [207]. Emergency cricothyroidotomy can result in serious complications [216, 262], although these are infrequent when staff are well trained [263–267]. The technique uses low-pressure ventilation through a cuffed tube in the trachea.

A simplified cricothyroidotomy technique can be performed in 30 s [268–270]. This 4-step technique consists of:

**Step 1** Identification of the cricothyroid membrane.

**Step 2** Horizontal stab incision (No. 20 scalpel) through skin and membrane.

**Step 3** Caudal traction on the cricoid membrane with a tracheal hook.

**Step 4** Intubation of the trachea.

The ATLS cricothyroidotomy technique includes blunt dilation of the incision made in step 2. It is important to avoid endobronchial intubation [271] when a tracheal tube is used.

Cricothyroidotomy is sometimes particularly difficult in the obese patient. Insertion of the tube can be facilitated by passage of an introducer (bougie) through the incision [272] or use of a tracheal retractor [270, 273–277].

Guidewire techniques of cricothyroidotomy have been developed. Some claim that these can restore the airway as quickly as the standard surgical technique [278], while others have found the guidewire technique to take longer [279], and to be less satisfactory, as a consequence of kinking of the wires [280]. It has recently been shown that the technique can be performed in 40 s after practice in a manikin [281]. The Melker™ guidewire intubation set is now available with a cuffed tube. This technique seems promising but further reports are needed before it can be considered a core rescue technique.

Cannula and surgical cricothyroidotomy each have advantages and disadvantages. Cannula cricothyroidotomy involves a smaller incision with less risk of bleeding. It may be the technique of choice when dedicated equipment is immediately available and staff are trained in its use. If it cannot be performed rapidly, is ineffective [242, 245, 258] or causes complications [258, 282], surgical

cricothyroidotomy should be performed immediately [242, 245, 258, 282]. Surgical cricothyroidotomy is more invasive. It can be performed very rapidly and will allow effective ventilation with low-pressure sources.

Invasive airway access is a temporary measure to restore oxygenation. Definitive airway management will follow. This may be a formal tracheostomy, but tracheal intubation will be possible in some patients [257, 283].

## Discussion

A major impetus for the development of clinical guidelines was the finding of marked variations in medical practice and the belief that guidelines could be used to improve standards [284–286]. Guidelines have much to offer in the management of infrequent, life-threatening situations [287, 288]. In particular, following the resuscitation guidelines improves outcome [12, 289, 290]. There is evidence that use of airway guidelines has improved airway management in France [291].

Unanticipated difficult intubation will continue to occur. A new approach is needed to ensure optimal management of infrequent airway problems. Medicine has lagged behind the military [292–297] and the airline industry [298–300], which use guidelines and regular practice of drills to train staff to deal with infrequent emergencies. Allnutt states that ‘there is no excuse for poorly designed procedures when human life is at risk’ [301].

Tunstall first described a failed intubation drill [148] for use in obstetric anaesthesia. Although of proven value [302, 303], some components such as the lateral position are no longer widely supported [146, 304–306] and new devices such as the LMA<sup>TM</sup> have changed management [307]. There are now new failed intubation drills in obstetrics [308].

There is a need for definitive national airway guidelines for management of unanticipated difficult intubation in the non-obstetric adult patient [309]. They should be easy to learn and to implement as simple drills [310]. They should include a minimum number of techniques of proven value. They should be based on a practical approach to airway management, using skills which are widely available. The DAS guidelines are designed to fulfil these requirements. Simple, clear and definitive flow-charts have been produced to cover three important clinical scenarios. They do not proscribe the use of other techniques by those experienced in their use, provided oxygenation is maintained and airway trauma is prevented.

The DAS guidelines have been developed by consensus and are based on experience and evidence. The principles

applied are maintenance of oxygenation and prevention of trauma. Maintenance of oxygenation is achieved primarily by using the face mask and LMA<sup>TM</sup>. Prevention of trauma is achieved by limiting the number of attempts at intubation and by using the ILMA<sup>TM</sup> as a dedicated airway to allow oxygenation, while tracheal intubation is achieved under vision with the fibroscope.

Controlled studies cannot be performed in unanticipated difficult intubation. The evidence basis of these guidelines best fits the description of expert committee reports, opinions and experience, and is defined as category IV evidence [311]. The DAS recommendations are therefore officially strength D. All DAS recommendations are supported by at least two case reports or series, the strongest evidence available for infrequent emergency situations.

We hope that implementation of these guidelines will reduce the incidence of airway trauma and hypoxaemic damage associated with unanticipated difficult intubation and result in better outcomes for our patients.

The techniques which have been recommended in these plans should be an integral part of initial and continuing airway training. This can be achieved by acquisition of knowledge in classroom teaching, learning practical skills using manikins in workshops [281], and use in clinical practice, when appropriate [312, 313].

There are equipment implications in these guidelines. All the equipment described should be available for regular practice. A cart containing the equipment should be located no more than a couple of minutes from every location where anaesthesia is administered. Recommended equipment lists will be published on the DAS Web Site (<http://www.das.uk.com>).

We hope that these guidelines will be tested in a clinical environment [314] and further modifications will certainly follow. We seek constructive suggestions.

*Notes on figures:* Figures 2–4 in this paper contain a considerable amount of detail in order to maximise their value for training. Both these and simpler versions will be available from the DAS Web Site (<http://www.das.uk.com>) in the future. Others may wish to produce different versions for their own purposes.

## Acknowledgements

We gratefully acknowledge the suggestions and constructive criticism from many members of the Difficult Airway Society and other colleagues. This paper would not have been possible without the help of many librarians.

*Conflict of interest:* Various companies manufacturing/distributing equipment mentioned in the guidelines have contributed to meetings and workshops held by DAS or by the authors. Neither DAS or any of the authors have any commercial links with any of these companies.

## References

- 1 Utting JE. Pitfalls in anaesthetic practice. *Anaesthesia* 1987; **59**: 877–90.
- 2 Gannon K. Mortality associated with anaesthesia. A case review study. *Anaesthesia* 1991; **46**: 962–6.
- 3 Domino KB, Posner KL, Caplan RA, Cheney FW. Airway injury during anesthesia: a closed claims analysis. *Anesthesiology* 1999; **91**: 1703–11.
- 4 Benumof JL, Scheller MS. The importance of transtracheal jet ventilation in the management of the difficult airway. *Anesthesiology* 1989; **71**: 769–78.
- 5 American Society of Anesthesiologists Task Force on Management of the Difficult Airway. Practice Guidelines for Management of the Difficult Airway. *Anesthesiology* 1993; **78**: 597–602.
- 6 American Society of Anesthesiologists Task Force on Management of the Difficult Airway. Practice guidelines for management of the difficult airway. An updated report. *Anesthesiology* 2003; **95**: 1269–77.
- 7 Boisson-Bertrand D, Bourgain JL, Camboulives J, et al. Intubation difficile. Société française d'anesthésie et de réanimation. Expertise collective. *Annales Françaises D'Anesthésie et de Réanimation* 1996; **15**: 207–14.
- 8 Crosby ET, Cooper RM, Douglas MJ, et al. The unanticipated difficult airway with recommendations for management. *Canadian Journal of Anaesthesia* 1998; **45**: 757–76.
- 9 SIAARTI Task Force on Difficult Airway Management. L'intubazione difficile e la difficoltà di controllo delle vie aeree nell'adulto (SIAARTI). *Minerva Anestesiologica* 1998; **64**: 361–71.
- 10 Nolan J, Gwinnutt C. European guidelines on resuscitation. Simplifications should make them easier to teach and implement. *British Medical Journal* 1998; **316**: 1844–5.
- 11 Bossaert L. Adult Advanced Life Support. In: Bossaert L, ed. *European Resuscitation Council Guidelines for Resuscitation*. Amsterdam: Elsevier, 1998:35–61.
- 12 Sanders AB. The development of AHA (American Heart Association) guidelines for emergency cardiac care. *Respiratory Care* 1995; **40**: 338–44.
- 13 Field MJ. Overview: prospects and options for local and national guidelines in the courts. *Joint Commission Journal on Quality Improvement* 1993; **19**: 313–8.
- 14 Renvoize EB, Hampshire SM, Pinder JM, Ayres P. What are hospitals doing about clinical guidelines? *Quality in Health Care* 1997; **6**: 187–91.
- 15 Deutsch EV. A stilet for endotracheal intubation. *Anesthesiology* 1951; **15**: 667–70.
- 16 Linder GS. New polyolefin-coated endotracheal tube stylet. *Anesthesia and Analgesia* 1974; **53**: 341–2.
- 17 Williamson R. An alternative to bougies for difficult intubation. *British Journal of Hospital Medicine* 1990; **43**: 184.
- 18 Smith M, Buist RJ, Mansour NY. A simple method to facilitate difficult intubation. *Canadian Journal of Anaesthesia* 1990; **37**: 144–5.
- 19 Henderson JJ. Solutions to the problem of difficult tracheal tube passage associated with the paraglossal straight laryngoscopy technique. *Anaesthesia* 1999; **54**: 601–2.
- 20 Kubota Y, Toyoda Y, Kubota H, Ueda Y. Shaping tracheal tubes. *Anaesthesia* 1987; **42**: 896.
- 21 Henderson JJ. Intubation techniques for unanticipated difficult intubation: Stylets and introducers. In: Paschen H, Dörge V, eds. *Der Schwere Atemweg*. Heidelberg: Springer-Verlag, 2003.
- 22 Davies JM, Weeks S, Crone LA, Pavlin E. Difficult intubation in the parturient. *Canadian Journal of Anaesthesia* 1989; **36**: 668–74.
- 23 Copley M, Vaughan RS. Recognition and management of difficult airway problems. *British Journal of Anaesthesia* 1992; **68**: 90–7.
- 24 Cook TM. A new practical classification of laryngeal view. *Anaesthesia* 2000; **55**: 274–9.
- 25 Cormack RS, Lehane J. Difficult tracheal intubation in obstetrics. *Anaesthesia* 1984; **39**: 1105–11.
- 26 Hames KC, Pandit JJ, Marfin AG, Papat MT, Yentis SM. Use of the bougie in simulated difficult intubation. 1. Comparison of the single-use bougie with the fibroscope. *Anaesthesia* 2003; **58**: 846–51.
- 27 Benumof JL. Difficult laryngoscopy: obtaining the best view. *Canadian Journal of Anaesthesia* 1994; **41**: 361–5.
- 28 Wilson ME, Spiegelhalter D, Robertson JA, Lesser P. Predicting difficult intubation. *British Journal of Anaesthesia* 1988; **61**: 211–6.
- 29 Benumof JL, Cooper SD. Quantitative improvement in laryngoscopic view by optimal external laryngeal manipulation. *Journal of Clinical Anesthesia* 1996; **8**: 136–40.
- 30 Vanner RG, Clarke P, Moore WJ, Raftery S. The effect of cricoid pressure and neck support on the view at laryngoscopy. *Anaesthesia* 1997; **52**: 896–900.
- 31 Ochroch EA, Levitan RM. A videographic analysis of laryngeal exposure comparing the articulating laryngoscope and external laryngeal manipulation. *Anesthesia and Analgesia* 2001; **92**: 267–70.
- 32 Yentis SM. The effects of single-handed and bimanual cricoid pressure on the view at laryngoscopy. *Anaesthesia* 1997; **52**: 332–5.
- 33 Knill RL. Difficult laryngoscopy made easy with a 'BURP'. *Canadian Journal of Anaesthesia* 1993; **40**: 279–82.
- 34 Relle A. Difficult laryngoscopy – 'BURP'. *Canadian Journal of Anaesthesia* 1993; **40**: 798–9.
- 35 Lam AM. The difficult airway and BURP – a truly Canadian perspective. *Canadian Journal of Anaesthesia* 1999; **46**: 298–9.
- 36 Gabbott DA. Laryngoscopy using the McCoy laryngoscope after application of a cervical collar. *Anaesthesia* 1996; **51**: 812–4.
- 37 Laurent SC, de Melo AE, Alexander-Williams JM. The use of the McCoy laryngoscope in patients with simulated cervical spine injuries. *Anaesthesia* 1996; **51**: 74–5.
- 38 Chisholm DG, Calder I. Experience with the McCoy laryngoscope in difficult laryngoscopy. *Anaesthesia* 1997; **52**: 906–8.

- 39 Uchida T, Hikawa Y, Saito Y, Yasuda K. The McCoy levering laryngoscope in patients with limited neck extension. *Canadian Journal of Anaesthesia* 1997; **44**: 674–6.
- 40 Harioka T, Nomura K, Mukaida K, Hosoi S, Nakao S. The McCoy laryngoscope, external laryngeal pressure, and their combined use. *Anaesthesia and Intensive Care* 2000; **28**: 537–9.
- 41 Henderson JJ. Questions about the Macintosh laryngoscope and technique of laryngoscopy. *European Journal of Anaesthesiology* 2000; **17**: 2–5.
- 42 Henderson JJ, Frerk CM. Remember the straight laryngoscope. *British Journal of Anaesthesia* 2002; **88**: 151–2.
- 43 Henderson JJ. Development of the 'gum-elastic bougie'. *Anaesthesia* 2003; **58**: 103–4.
- 44 Morris J, Cook TM. Rapid sequence induction: a national survey of practice. *Anaesthesia* 2001; **56**: 1090–7.
- 45 Gataure PS, Vaughan RS, Latto IP. Simulated difficult intubation. Comparison of the gum elastic bougie and the stylet. *Anaesthesia* 1996; **51**: 935–8.
- 46 Sellers WFS, Jones GW. Difficult tracheal intubation. *Anaesthesia* 1986; **41**: 93.
- 47 Kidd JF, Dyson A, Latto IP. Successful difficult intubation. Use of the gum elastic bougie. *Anaesthesia* 1988; **43**: 437–8.
- 48 Latto IP, Stacey M, Mecklenburgh J, Vaughan RS. Survey of the use of the gum elastic bougie in clinical practice. *Anaesthesia* 2002; **57**: 379–84.
- 49 Nolan JP, Wilson ME. An evaluation of the gum elastic bougie. Intubation times and incidence of sore throat. *Anaesthesia* 1992; **47**: 878–81.
- 50 Dogra S, Falconer R, Latto IP. Successful difficult intubation. Tracheal tube placement over a gum-elastic bougie. *Anaesthesia* 1990; **45**: 774–6.
- 51 Cossham PS. Difficult intubation. *British Journal of Anaesthesia* 1985; **57**: 239.
- 52 Klafra JM. Flexible tracheal tubes facilitate fiberoptic intubation. *Anesthesia and Analgesia* 1994; **79**: 1211–2.
- 53 Koh KF, Hare JD, Calder I. Small tubes revisited. *Anaesthesia* 1998; **53**: 46–50.
- 54 Hakala P, Randell T, Valli H. Comparison between tracheal tubes for orotracheal fiberoptic intubation. *British Journal of Anaesthesia* 1999; **82**: 135–6.
- 55 Calder I. When the endotracheal tube will not pass over the flexible fiberoptic bronchoscope. *Anesthesiology* 1992; **77**: 398.
- 56 Brull SJ, Wiklund R, Ferris C, et al. Facilitation of fiberoptic orotracheal intubation with a flexible tracheal tube. *Anesthesia and Analgesia* 1994; **78**: 746–8.
- 57 Lucas DN, Yentis SM. A comparison of the intubating laryngeal mask tracheal tube with a standard tracheal tube for fiberoptic intubation. *Anaesthesia* 2000; **55**: 358–61.
- 58 Barker KF, Bolton P, Cole S, Coe PA. Ease of laryngeal passage during fiberoptic intubation: a comparison of three endotracheal tubes. *Acta Anaesthesiologica Scandinavica* 2001; **45**: 624–6.
- 59 Kristensen M. The Parker Flex-Tip tube versus a standard tube for fiberoptic orotracheal intubation. A randomized double-blind study. *Anesthesiology* 2003; **98**: 354–8.
- 60 Wilkes AR, Hodzovic I, Latto IP. Comparison of the peak forces that can be exerted by multiple-use and single-use bougies *in vitro*. *British Journal of Anaesthesia* 2002; **89**: 671.
- 61 Annamaneni R, Hodzovic I, Wilkes AR, Latto IP. A comparison of simulated difficult intubation with multiple-use and single-use bougies in a manikin. *Anaesthesia* 2003; **58**: 45–9.
- 62 Marfin AG, Pandit JJ, Hames KC, Popat MT, Yentis SM. Use of bougie in simulated difficult intubation. 2. Comparison of single-use bougie with multiple-use bougie. *Anaesthesia* 2003; **58**: 852–5.
- 63 Ovassapian A. Management of the difficult airway. In: Ovassapian A, ed. *Fiberoptic Endoscopy and the Difficult Airway*. Philadelphia: Lippincott-Raven, 1996: 201–30.
- 64 Heidegger T, Gerig HJ, Ulrich B, Kreienbuhl G. Validation of a simple algorithm for tracheal intubation: daily practice is the key to success in emergencies – an analysis of 13,248 intubations. *Anesthesia and Analgesia* 2001; **92**: 517–22.
- 65 Gorback MS. Management of the challenging airway with the Bullard laryngoscope. *Journal of Clinical Anesthesia* 1991; **3**: 473–7.
- 66 Mendel P, Bristow A. Anaesthesia for procedures on the larynx and pharynx. The use of the Bullard laryngoscope in conjunction with high frequency jet ventilation. *Anaesthesia* 1993; **48**: 263–5.
- 67 Midttun M, Hansen CL, Jensen K, Pedersen T, Laerkholm Hansen C. The Bullard laryngoscope. Reports of two cases of difficult intubation. *Acta Anaesthesiologica Scandinavica* 1994; **38**: 300–2.
- 68 Shigematsu T, Miyazawa N, Kobayashi M, Yorozu T, Toyoda Y, Morisaki H. Nasal intubation with Bullard laryngoscope: a useful approach for difficult airways. *Anesthesia and Analgesia* 1994; **79**: 132–5.
- 69 Cohn AI, McGraw SR, King WH. Awake intubation of the adult trachea using the Bullard laryngoscope. *Canadian Journal of Anaesthesia* 1995; **42**: 246–8.
- 70 Hastings RH, Vigil AC, Hanna R, Yang BY, Sartoris DJ. Cervical spine movement during laryngoscopy with the Bullard, Macintosh, and Miller laryngoscopes. *Anesthesiology* 1995; **82**: 859–69.
- 71 Watts AD, Gelb AW, Bach DB, Pelz DM. Comparison of the Bullard and Macintosh laryngoscopes for endotracheal intubation of patients with a potential cervical spine injury. *Anesthesiology* 1997; **87**: 1335–42.
- 72 Smith CE, Kareti M. Fiberoptic laryngoscopy (WuScope) for double-lumen endobronchial tube placement in two difficult intubation patients. *Anesthesiology* 2000; **93**: 906–7.
- 73 Andrews SR, Mabey MF. Tubular fiberoptic laryngoscope (WuScope) and lingual tonsil airway obstruction. *Anesthesiology* 2000; **93**: 904–5.
- 74 Sprung J, Weingarten T, Dilger J. The use of the WuScope fiberoptic laryngoscope for tracheal intubation in complex clinical situations. *Anesthesiology* 2003; **98**: 263–5.

- 75 Shulman GB, Connelly NR. A comparison of the Bullard laryngoscope versus the flexible fiberoptic bronchoscope during intubation in patients afforded inline stabilization. *Journal of Clinical Anesthesia* 2001; **13**: 182–5.
- 76 Agro F, Hung O, Cataldo R, Carassiti M, Gherardi S. Lightwand intubation using the Trachlight: a brief review of current knowledge. *Canadian Journal of Anaesthesia* 2001; **48**: 592–9.
- 77 Steinert R, Lullwitz E. Mißlungene Intubation mit Kasuistiken. *HNO* 1987; **35**: 439–42.
- 78 Caplan RA, Posner KL, Ward RJ, Cheney FW. Adverse respiratory events in anesthesia: a closed claims analysis. *Anesthesiology* 1990; **72**: 828–33.
- 79 Rose DK, Cohen MM. The incidence of airway problems depends on the definition used. *Canadian Journal of Anaesthesia* 1996; **43**: 30–4.
- 80 Gilbert SM. *Wrongful Death*. New York: W.W. Norton, 1997.
- 81 Miller CG. Management of the Difficult Intubation in Closed Malpractice Claims. *ASA Newsletter* June 2000 [www.asahq.org/Newsletters/2000/06](http://www.asahq.org/Newsletters/2000/06): 64.
- 82 Benumof JL. The American Society of Anesthesiologists' management of the difficult airway algorithm and explanation-analysis of the algorithm. In: Benumof JL, ed. *Airway Management. Principles and Practice*. St. Louis: Mosby, 1996:143–56.
- 83 Groves J, Edwards N, Hood G. Difficult intubation following thoracic trauma. *Anaesthesia* 1994; **49**: 698–9.
- 84 Wattenmaker I, Concepcion M, Hibberd P, Lipson S. Upper-airway obstruction and perioperative management of the airway in patients managed with posterior operations on the cervical spine for rheumatoid arthritis. *Journal of Bone and Joint Surgery – American* 1994; **76**: 360–5.
- 85 Fear DW. Failed intubation in the parturient. *Canadian Journal of Anaesthesia* 1989; **36**: 614–6.
- 86 Williams KN, Carli F, Cormack RS. Unexpected difficult laryngoscopy: a prospective survey in routine general surgery. *British Journal of Anaesthesia* 1991; **66**: 38–44.
- 87 Charters P, O'Sullivan E. The 'dedicated airway': a review of the concept and an update of current practice. *Anaesthesia* 1999; **54**: 778–86.
- 88 Benumof JL. Laryngeal mask airway and the ASA difficult airway algorithm. *Anesthesiology* 1996; **84**: 686–99.
- 89 Brain AI, Verghese C, Addy EV, Kapila A, Brimacombe J. The intubating laryngeal mask. II. A preliminary clinical report of a new means of intubating the trachea. *British Journal of Anaesthesia* 1997; **79**: 704–9.
- 90 Caponas G. Intubating laryngeal mask airway. *Anaesthesia and Intensive Care* 2002; **30**: 551–69.
- 91 Kapila A, Addy EV, Verghese C, Brain AIJ. The intubating laryngeal mask airway: an initial assessment of performance. *British Journal of Anaesthesia* 1997; **79**: 710–3.
- 92 Ferson DZ, Supkis DE, Rahlfs TF, Jones RL. Evaluation of the intubating laryngeal mask as a primary airway device and a guide for blind endotracheal intubation. *Anesthesiology* 1997; **87**: A485.
- 93 Agrò F, Brimacombe J, Carassiti M, Marchionni L, Morelli A, Cataldo R. The intubating laryngeal mask. Clinical appraisal of ventilation and blind tracheal intubation in 110 patients. *Anaesthesia* 1998; **53**: 1084–90.
- 94 Baskett PJF, Parr MJA, Nolan JP. The intubating laryngeal mask. Results of a multicentre trial with experience of 500 cases. *Anaesthesia* 1998; **53**: 1174–9.
- 95 Chan YW, Kong CF, Kong CS, Hwang NC, Ip-Yam PC. The intubating laryngeal mask airway (ILMA): initial experience in Singapore. *British Journal of Anaesthesia* 1998; **81**: 610–1.
- 96 Murashima K, Fukutome T, Brimacombe J. A comparison of two silicone-reinforced tracheal tubes with different bevels for use with the intubating laryngeal mask. *Anaesthesia* 1999; **54**: 1198–200.
- 97 Kihara S, Watanabe S, Taguchi N, Suga A, Brimacombe JR. Tracheal intubation with the Macintosh laryngoscope versus intubating laryngeal mask airway in adults with normal airways. *Anaesthesia and Intensive Care* 2000; **28**: 281–6.
- 98 van Vlymen JM, Coloma M, Tongier WK, White PF. Use of the intubating laryngeal mask airway: are muscle relaxants necessary? *Anesthesiology* 2000; **93**: 340–5.
- 99 Cros AM, Colombani S. Preliminary study of intubation with a new laryngeal mask for difficult intubation. *Anesthesiology* 1997; **87**: A482.
- 100 Fukutome T, Amaha K, Nakazawa K, Kawamura T, Noguchi H. Tracheal intubation through the intubating laryngeal mask airway (LMA-Fastrach) in patients with difficult airways. *Anaesthesia and Intensive Care* 1998; **26**: 387–91.
- 101 Agro F, Brimacombe J, Brain AI, Marchionni L, Cataldo R. The intubating laryngeal mask for maxillo-facial trauma. *European Journal of Anaesthesiology* 1999; **16**: 263–4.
- 102 Nakazawa K, Tanaka N, Ishikawa S, et al. Using the intubating laryngeal mask airway (LMA-Fastrach) for blind endotracheal intubation in patients undergoing cervical spine operation. *Anesthesia and Analgesia* 1999; **89**: 1319–21.
- 103 Joo HS, Kapoor S, Rose DK, Naik VN. The intubating laryngeal mask airway after induction of general anesthesia versus awake fiberoptic intubation in patients with difficult airways. *Anesthesia and Analgesia* 2001; **92**: 1342–6.
- 104 Ferson DZ, Rosenblatt WH, Johansen MJ, Osborn I, Ovassapian A. Use of the intubating LMA-Fastrach in 254 patients with difficult-to-manage airways. *Anesthesiology* 2001; **95**: 1175–81.
- 105 Langeron O, Semjen F, Bourgain JL, Marsac A, Cros AM. Comparison of the intubating laryngeal mask airway with the fiberoptic intubation in anticipated difficult airway management. *Anesthesiology* 2001; **94**: 968–72.
- 106 Lu PP, Brimacombe J, Ho ACY, Shyr MH, Liu HP. The intubating laryngeal mask airway in severe ankylosing spondylitis. *Canadian Journal of Anaesthesia* 2001; **48**: 1015–9.

- 107 Asai T, Shingu K. Tracheal intubation through the intubating laryngeal mask in patients with unstable necks. *Acta Anaesthesiologica Scandinavica* 2001; **45**: 818–22.
- 108 Dimitriou V, Voyagis GS. Blind intubation via the ILMA: what about accidental oesophageal intubation? *British Journal of Anaesthesia* 1999; **82**: 478–9.
- 109 Dimitriou V, Voyagis GS. The intubating laryngeal mask airway (ILMA): disadvantage of being a blind technique. *European Journal of Anaesthesiology* 1999; **16**: 418–9.
- 110 Dimitriou V, Voyagis GS, Brimacombe J. Flexible lightwand-guided intubation through the ILM. *Acta Anaesthesiologica Scandinavica* 2001; **45**: 263–4.
- 111 Kihara S, Watanabe S, Taguchi N, Suga A, Brimacombe JR. A comparison of blind and lightwand-guided tracheal intubation through the intubating laryngeal mask. *Anaesthesia* 2000; **55**: 427–31.
- 112 Chan PL, Lee TW, Lam KK, Chan WS. Intubation through intubating laryngeal mask airway with and without a lightwand: a randomized comparison. *Anaesthesia and Intensive Care* 2001; **29**: 255–9.
- 113 Pandit JJ, Maclachlan K, Dravid RM, Popat MT. Comparison of times to achieve tracheal intubation with three techniques using the laryngeal mask or intubating laryngeal mask airway. *Anaesthesia* 2002; **57**: 128–32.
- 114 Parr MJA, Gregory M, Baskett PJF. The intubating laryngeal mask. Use in failed and difficult intubation. *Anaesthesia* 1998; **53**: 343–8.
- 115 Brain AJ, Vergheze C. *The Intubating Laryngeal Mask Airway Instruction Manual*. 1st edn. Maidenhead, Berkshire: Intavent Ltd, 1998.
- 116 Ferson DZ, Brimacombe J, Brain AI, Vergheze C. The intubating laryngeal mask airway. *International Anesthesiology Clinics* 1998; **36**: 183–209.
- 117 Aoyama K, Yasunaga E, Takenaka I, Kadoya T, Sata T, Shigematsu A. Positive pressure ventilation during fiberoptic intubation: comparison of the laryngeal mask airway, intubating laryngeal mask and endoscopy mask techniques. *British Journal of Anaesthesia* 2002; **88**: 246–54.
- 118 Keller C, Brimacombe J. Pharyngeal mucosal pressures, airway sealing pressures, and fiberoptic position with the intubating versus the standard laryngeal mask airway. *Anesthesiology* 1999; **90**: 1001–6.
- 119 Kihara S, Yaguchi Y, Brimacombe J, Watanabe S, Taguchi N. Routine use of the intubating laryngeal mask airway results in increased upper airway morbidity. *Canadian Journal of Anaesthesia* 2001; **48**: 604–8.
- 120 Heath ML, Allagani J. Intubation through the laryngeal mask. A technique for unexpected difficult intubation. *Anaesthesia* 1991; **46**: 545–8.
- 121 Lim SL, Tay DH, Thomas E. A comparison of three types of tracheal tube for use in laryngeal mask assisted blind orotracheal intubation. *Anaesthesia* 1994; **49**: 255–7.
- 122 Asai T. Blind tracheal intubation through the laryngeal mask. *Canadian Journal of Anaesthesia* 1996; **43**: 1275.
- 123 Silk JM, Hill HM, Calder I. Difficult intubation and the Laryngeal Mask. *European Journal of Anaesthesiology* 1991; **4** (Suppl): 47–51.
- 124 Koga K, Asai T, Latto IP, Vaughan RS. Effect of the size of a tracheal tube and the efficacy of the use of the laryngeal mask for fibroscope-aided tracheal intubation. *Anaesthesia* 1997; **52**: 131–5.
- 125 Asai T, Latto P. Role of the laryngeal mask in patients with difficult tracheal intubation and difficult ventilation. In: Latto IP, Vaughan RS, eds. *Difficulties in Tracheal Intubation*. London: W.B. Saunders, 1997: 177–96.
- 126 Popat MT. *Practical Fiberoptic Intubation*. Oxford: Butterworth-Heinemann, 2001.
- 127 Asai T. Tracheal intubation through the laryngeal mask airway. *Anesthesiology* 1996; **85**: 439.
- 128 Roth DM, Benumof JL. Intubation through a laryngeal mask airway with a nasal RAE tube: stabilization of the proximal end of the tube. *Anesthesiology* 1996; **85**: 1220.
- 129 Chen L, Sher SA, Aukburg SJ. Continuous ventilation during trans-laryngeal mask airway fiberoptic bronchoscope-aided tracheal intubation. *Anesthesia and Analgesia* 1996; **82**: 891–2.
- 130 Preis C, Preis I. Concept for easy fiberoptic intubation via a laryngeal airway mask. *Anesthesia and Analgesia* 1999; **89**: 803–4.
- 131 Barnett RA, Ochroch EA. Augmented fiberoptic intubation. *Critical Care Clinics* 2000; **16**: 453–62.
- 132 Alexander R. Do not remove the laryngeal mask airway. *Anesthesia and Analgesia* 1999; **89**: 536–7.
- 133 Atherton DP, O'Sullivan E, Lowe D, Charters P. A ventilation-exchange bougie for fiberoptic intubations with the laryngeal mask airway. *Anaesthesia* 1996; **51**: 1123–6.
- 134 Atherton DPL, O'Sullivan E, Charters P. Modification to the ventilation exchange bougie. *Anaesthesia* 1997; **52**: 611–2.
- 135 Benumof JLASA Difficult Airway algorithm. New thoughts and considerations. In: Hagberg C, ed. *Handbook of Difficult Airway Management*. Philadelphia: Churchill Livingstone, 2000: 31–48.
- 136 Machlin HA, Myles PS, Berry CB, Butler PJ, Story DA, Heath BJ. End-tidal oxygen measurement compared with patient factor assessment for determining preoxygenation time. *Anaesthesia and Intensive Care* 1993; **21**: 409–13.
- 137 Sellick BA. Cricoid pressure to control regurgitation of stomach contents during induction of anesthesia. *Lancet* 1961; **ii**: 404–6.
- 138 Bruin G, Buckley N. Intubating conditions and correct application of cricoid pressure during rapid sequence induction: who should hold the mask? *Canadian Journal of Anaesthesia* 1997; **44**: 900.
- 139 Vanner R. Techniques of cricoid pressure. *Anaesthesia and Intensive Care Medicine* 2001; **2**: 362–3.
- 140 Shorten GD, Alfile PH, Gliklich RE. Airway obstruction following application of cricoid pressure. *Journal of Clinical Anesthesia* 1991; **3**: 403–5.
- 141 Georgescu A, Miller JN, Lecklitner ML. The Sellick maneuver causing complete airway obstruction. *Anesthesia and Analgesia* 1992; **74**: 457–9.
- 142 Shorten GD. Airway obstruction from cricoid pressure. *Anesthesia and Analgesia* 1993; **76**: 668.

- 143 Shorten GD. Airway obstruction on cricoid pressure is not glottic. *Anesthesia and Analgesia* 1994; **78**: 1203.
- 144 Allman KG. The effect of cricoid pressure application on airway patency. *Journal of Clinical Anesthesia* 1995; **7**: 197–9.
- 145 Palmer JHM, Ball DR. The effect of cricoid pressure on the cricoid cartilage and vocal cords: an endoscopic study in anaesthetised patients. *Anaesthesia* 2000; **55**: 263–8.
- 146 Hocking G, Roberts FL, Thew ME. Airway obstruction with cricoid pressure and lateral tilt. *Anaesthesia* 2001; **56**: 825–8.
- 147 Hartsilver EL, Vanner R.G. Airway obstruction with cricoid pressure. *Anaesthesia* 2000; **55**: 208–11.
- 148 Tunstall ME. Failed intubation drill. *Anaesthesia* 1976; **31**: 850.
- 149 Ansermino JM, Blogg CE, Carrie LE. Failed tracheal intubation at caesarean section and the laryngeal mask. *British Journal of Anaesthesia* 1992; **68**: 118.
- 150 Chadwick IS, Vohra A. Anaesthesia for emergency Caesarean section using the Brain laryngeal mask airway. *Anaesthesia* 1989; **44**: 261–2.
- 151 Brimacombe J, Berry A, White A. An algorithm for use of the laryngeal mask airway during failed intubation in the patient with a full stomach. *Anesthesia and Analgesia* 1993; **77**: 398–9.
- 152 Christian AS. Failed obstetric intubation. *Anaesthesia* 1990; **45**: 995.
- 153 Asai T, Morris S. The role of the laryngeal mask for failed tracheal intubation in the patient with a 'full stomach'. *Anesthesia and Analgesia* 1994; **78**: 817–9.
- 154 Brain AI, Verghese C, Strube PJ. The LMA 'ProSeal' – a laryngeal mask with an oropharyngeal vent. *British Journal of Anaesthesia* 2000; **84**: 650–4.
- 155 Keller C, Brimacombe J. Mucosal pressure and oropharyngeal leak pressure with the ProSeal versus laryngeal mask airway in anaesthetized paralysed patients. *British Journal of Anaesthesia* 2000; **85**: 262–6.
- 156 Brimacombe J, Keller C. The ProSeal laryngeal mask airway: a randomized, crossover study with the standard laryngeal mask airway in paralyzed, anesthetized patients. *Anesthesiology* 2000; **93**: 104–9.
- 157 Brimacombe J, Keller C, Fullekrug B, et al. A multicenter study comparing the ProSeal and Classic laryngeal mask airway in anesthetized, nonparalyzed patients. *Anesthesiology* 2002; **96**: 289–95.
- 158 Brimacombe J, Keller C, Brimacombe L. A comparison of the laryngeal mask airway ProSeal and the laryngeal tube airway in paralyzed anesthetized adult patients undergoing pressure-controlled ventilation. *Anesthesia and Analgesia* 2002; **95**: 770–6.
- 159 Lu PP, Brimacombe J, Yang C, Shyr M. ProSeal versus the Classic laryngeal mask airway for positive pressure ventilation during laparoscopic cholecystectomy. *British Journal of Anaesthesia* 2002; **88**: 824–7.
- 160 Cook TM, Nolan JP, Verghese C, et al. Randomized crossover comparison of the proseal with the classic laryngeal mask airway in unparalysed anaesthetized patients. *British Journal of Anaesthesia* 2002; **88**: 527–33.
- 161 Keller C, Brimacombe J, Kleinsasser A, Loeckinger A. Does the ProSeal laryngeal mask airway prevent aspiration of regurgitated fluid? *Anesthesia and Analgesia* 2000; **91**: 1017–20.
- 162 Brimacombe J, Keller C. Airway protection with the ProSeal laryngeal mask airway. *Anaesthesia and Intensive Care* 2001; **29**: 288–91.
- 163 Evans NR, Llewellyn RL, Gardner SV, James MF. Aspiration prevented by the ProSeal laryngeal mask airway: a case report. *Canadian Journal of Anaesthesia* 2002; **49**: 413–6.
- 164 Evans NR, Gardner SV, James MF. ProSeal laryngeal mask protects against aspiration of fluid in the pharynx. *British Journal of Anaesthesia* 2002; **88**: 584–7.
- 165 Brimacombe J, Keller C, Berry A. Gastric insufflation with the ProSeal laryngeal mask. *Anesthesia and Analgesia* 2001; **92**: 1614–5.
- 166 Stix MS, Borromeo CJ, O'Connor CJ Jr. Esophageal insufflation with normal fiberoptic positioning of the ProSeal laryngeal mask airway. *Anesthesia and Analgesia* 2002; **94**: 1036–9.
- 167 Brimacombe J, Richardson C, Keller C, Donald S. Mechanical closure of the vocal cords with the laryngeal mask airway ProSeal. *British Journal of Anaesthesia* 2002; **88**: 296–7.
- 168 Stix MS, O'Connor CJ Jr. Maximum Minute Ventilation Test for the ProSeal™ Laryngeal Mask Airway. *Anesthesia and Analgesia* 2002; **95**: 1782–7.
- 169 Brimacombe J, Kennaugh S, Berry A, Keller C. Malposition of the ProSeal laryngeal mask. *Anesthesia and Analgesia* 2002; **94**: 1367.
- 170 Brain A. Esophageal breathing and upper airway obstruction with the ProSeal laryngeal mask. *Anesthesia and Analgesia* 2002; **94**: 1669–70.
- 171 Maltby JR, Bériault MT, Watson NC, Liepert D, Fick GH. The LMA-ProSeal is an effective alternative to tracheal intubation for laparoscopic cholecystectomy. *Canadian Journal of Anaesthesia* 2002; **49**: 857–62.
- 172 McIntyre JWR. Oropharyngeal and nasopharyngeal airways: I (1880–1995). *Canadian Journal of Anaesthesia* 1996; **43**: 629–35.
- 173 Airway and Ventilation Management Working Group of the European Resuscitation Council. Guidelines for the advanced management of the airway and ventilation during resuscitation. A statement by the Airway and Ventilation Management of the Working Group of the European Resuscitation Council. *Resuscitation* 1996; **31**: 201–30.
- 174 Crowhurst JA. Failed intubation management at caesarean section. *Anaesthesia and Intensive Care* 1991; **19**: 305.
- 175 Schade K, Borzotta A, Michaels A. Intracranial malposition of nasopharyngeal airway. *Journal of Trauma* 2000; **49**: 967–8.
- 176 Ansermino JM, Blogg CE. Cricoid pressure may prevent insertion of the laryngeal mask airway. *British Journal of Anaesthesia* 1992; **69**: 465–7.



- 177 Brimacombe J, White A, Berry A. Effect of cricoid pressure on ease of insertion of the laryngeal mask airway. *British Journal of Anaesthesia* 1993; **71**: 800–2.
- 178 Asai T, Barclay K, Power I, Vaughan RS. Cricoid pressure impedes placement of the laryngeal mask airway and subsequent tracheal intubation through the mask. *British Journal of Anaesthesia* 1994; **72**: 47–51.
- 179 Asai T, Barclay K, Power I, Vaughan RS. Cricoid pressure impedes placement of the laryngeal mask airway. *British Journal of Anaesthesia* 1995; **74**: 521–5.
- 180 Aoyama K, Takenaka I, Sata T, Shigematsu A. Cricoid pressure impedes positioning and ventilation through the laryngeal mask airway. *Canadian Journal of Anaesthesia* 1996; **43**: 1035–40.
- 181 Brimacombe JR, Berry A. Mechanical airway obstruction after cricoid pressure with the laryngeal mask airway. *Anesthesia and Analgesia* 1994; **78**: 604–5.
- 182 Brimacombe J, Berry A. Cricoid pressure and the LMA: efficacy and interpretation. *British Journal of Anaesthesia* 1994; **73**: 862–3.
- 183 Asai T, Barclay K, McBeth C, Vaughan RS. Cricoid pressure applied after placement of the laryngeal mask prevents gastric insufflation but inhibits ventilation. *British Journal of Anaesthesia* 1996; **76**: 772–6.
- 184 Benumof JL. Management of the difficult adult airway. With special emphasis on awake tracheal intubation. *Anesthesiology* 1991; **75**: 1087–110.
- 185 Jacobs HB. Emergency percutaneous transtracheal catheter and ventilator. *Journal of Trauma* 1972; **12**: 50–5.
- 186 Jacobs HB. Needle catheter brings oxygen to the trachea. *Journal of the American Medical Association* 1972; **222**: 1231–3.
- 187 Smith RB, Babinski M, Klain M, Pfaeffle H. Percutaneous transtracheal ventilation. *JACEP* 1976; **5**: 765–70.
- 188 Weymuller EA, Pavlin EG, Paugh D, Cummings CW. Management of difficult airway problems with percutaneous transtracheal ventilation. *Annals of Otology, Rhinology and Laryngology* 1987; **96**: 34–7.
- 189 Bradley PJ. Treatment of the patient with upper airway obstruction caused by cancer of the larynx. *Otolaryngology – Head and Neck Surgery* 1999; **120**: 737–41.
- 190 Gaitini LA, Vaida SJ, Mostafa S, et al. The Combitube in elective surgery: a report of 200 cases. *Anesthesiology* 2001; **94**: 79–82.
- 191 Baraka A, Salem R. The Combitube oesophageal-tracheal double lumen airway for difficult intubation. *Canadian Journal of Anaesthesia* 1993; **40**: 1222–3.
- 192 Urtubia RM, Aguila CM, Cumsille MA. Combitube: a study for proper use. *Anesthesia and Analgesia* 2000; **90**: 958–62.
- 193 Jaehnichen G, Golecki N, Lipp MD. A case report of difficult ventilation with the Combitube – valve-like upper airway obstruction confirmed by fiberoptic visualisation. *Resuscitation* 2000; **44**: 71–4.
- 194 Walls RM, Pollack CV Jr. Successful cricothyrotomy after thrombolytic therapy for acute myocardial infarction: a report of two cases. *Annals of Emergency Medicine* 2000; **35**: 188–91.
- 195 Banyai M, Falger S, Roggla M, et al. Emergency intubation with the Combitube in a grossly obese patient with bull neck. *Resuscitation* 1993; **26**: 271–6.
- 196 Tunstall ME, Geddes C. Failed intubation' in obstetric anaesthesia. An indication for use of the 'Esophageal Gastric Tube Airway. *British Journal of Anaesthesia* 1984; **56**: 659–61.
- 197 Bigenzahn W, Pesau B, Frass M. Emergency ventilation using the Combitube in cases of difficult intubation. *European Archives of Oto-Rhino-Laryngology* 1991; **248**: 129–31.
- 198 Eichinger S, Schreiber W, Heinz T, et al. Airway management in a case of neck impalement: Use of the oesophageal tracheal combitube airway. *British Journal of Anaesthesia* 1992; **68**: 534–5.
- 199 Klauser R, Roggla G, Pidlich J, Leithner C, Frass M. Massive upper airway bleeding after thrombolytic therapy: successful airway management with the Combitube. *Annals of Emergency Medicine* 1992; **21**: 431–3.
- 200 Mercer M. Respiratory failure after tracheal extubation in a patient with halo frame cervical spine immobilization – rescue therapy using the Combitube airway. *British Journal of Anaesthesia* 2001; **86**: 886–91.
- 201 Enlund M, Miregard M, Wennmalm K. The Combitube for failed intubation – instructions for use. *Acta Anaesthesiologica Scandinavica* 2001; **45**: 127–8.
- 202 Letheren MJ, Parry N, Slater RM. A complication of percutaneous tracheostomy whilst using the Combitube for airway control. *European Journal of Anaesthesiology* 1997; **14**: 464–6.
- 203 Klein H, Williamson M, Sue-Ling HM, Vucevic M, Quinn AC. Esophageal rupture associated with the use of the Combitube. *Anesthesia and Analgesia* 1997; **85**: 937–9.
- 204 Richards CF. Piriform sinus perforation during Esophageal-Tracheal Combitube placement. *Journal of Emergency Medicine* 1998; **16**: 37–9.
- 205 Vezina D, Lessard MR, Bussieres J, Topping C, Trepanier CA. Complications associated with the use of the Esophageal-Tracheal Combitube. *Canadian Journal of Anaesthesia* 1998; **45**: 76–80.
- 206 Hartmann T, Krenn CG, Zoeggeler A, Hoerauf K, Benumof JL, Krafft P. The oesophageal-tracheal Combitube Small Adult. *Anaesthesia* 2000; **55**: 670–5.
- 207 Tighe SQM. Failed tracheal intubation. *Anaesthesia* 1992; **47**: 356.
- 208 Yealy DM, Stewart RD. Translaryngeal cannula ventilation: continuing misconceptions. *Anesthesiology* 1987; **67**: 445–6.
- 209 Zornow MH, Thomas TC, Scheller MS. The efficacy of three different methods of transtracheal ventilation. *Canadian Journal of Anaesthesia* 1989; **36**: 624–8.
- 210 Blenko JW. Transtracheal jet ventilation. I. *Anesthesiology* 1990; **72**: 773–4.

- 211 Ryder IG, Paoloni CC, Harle CC. Emergency trans-tracheal ventilation: assessment of breathing systems chosen by anaesthetists. *Anaesthesia* 1996; **51**: 764–8.
- 212 Tighe SQM. Transtracheal ventilation. *Anaesthesia* 1996; **51**: 288–9.
- 213 Biro P, Moe KS. Emergency transtracheal jet ventilation in high grade airway obstruction. *Journal of Clinical Anesthesia* 1997; **9**: 604–7.
- 214 Wenig BL, Applebaum EL. Indications for and techniques of tracheotomy. *Clinics in Chest Medicine* 1991; **12**: 545–53.
- 215 Tunstall ME. Failed intubation in the parturient. *Canadian Journal of Anaesthesia* 1989; **36**: 611–3.
- 216 Gillespie MB, Eisele DW. Outcomes of emergency surgical airway procedures in a hospital-wide setting. *Laryngoscope* 1999; **109**: 1766–9.
- 217 Finucane B. The difficult airway – a Canadian perspective. *Canadian Journal of Anaesthesia* 1998; **45**: 713–8.
- 218 Toye FJ, Weinstein JD. Clinical experience with percutaneous tracheostomy and cricothyroidotomy in 100 patients. *Journal of Trauma* 1986; **26**: 1034–40.
- 219 Jason DR. Fatal angioedema associated with captopril. *Journal of Forensic Sciences* 1992; **37**: 1418–21.
- 220 Safar P, Pennickx J. Cricothyroid membrane puncture with special cannula. *Anesthesiology* 1967; **28**: 943–5.
- 221 Layman PR. An alternative to blind nasal intubation. *Anaesthesia* 1983; **38**: 165.
- 222 Department of Health. *Report on Confidential Enquiries into Maternal Deaths in England and Wales 1982–84. Report on Health and Social Subjects 34*. London: Her Majesty's Stationery Office, 1985.
- 223 Jones DH, Kohle SD. Unanticipated difficult airway secondary to lingual tonsillar hyperplasia. *Anesthesia and Analgesia* 1993; **77**: 1285–8.
- 224 Suh RH, Margulies DR, Hopp ML, Ault M, Shabot MM. Percutaneous dilatational tracheostomy: still a surgical procedure. *American Surgeon* 1999; **65**: 982–6.
- 225 Griggs WM, Myburgh JA, Worthley LIG. Urgent airway access – an indication for percutaneous tracheostomy? *Anaesthesia and Intensive Care* 1991; **19**: 586–7.
- 226 Aadahl P, Nordgard S. Percutaneous dilatational tracheostomy in a patient with thyroid cancer and severe airway obstruction. *Acta Anaesthesiologica Scandinavica* 1999; **43**: 483–5.
- 227 Mori M, Fujimoto J, Iwasaki H, Noguchi T. Emergency percutaneous dilatational cricothyroidotomy after failed intubation. *Anaesthesia and Intensive Care* 2002; **30**: 101–2.
- 228 Dob DP, McLure HA, Soni N. Failed intubation and emergency percutaneous tracheostomy. *Anaesthesia* 1998; **53**: 72–4.
- 229 Little CM, Parker MG, Tarnopolsky R. The incidence of vasculature at risk during cricothyroidostomy. *Annals of Emergency Medicine* 1986; **15**: 805–7.
- 230 Burkey B, Esclamado R, Morganroth M. The role of cricothyroidotomy in airway management. *Clinics in Chest Medicine* 1991; **12**: 561–71.
- 231 Bennett JDC, Guha SC, Sankar AB. Cricothyrotomy: the anatomical basis. *Journal of the Royal College of Surgeons of Edinburgh* 1996; **41**: 57–60.
- 232 Bossaert L. *European Resuscitation Council Guidelines for Resuscitation*. Amsterdam: Elsevier, 1998.
- 233 Department of Health. *Report on Confidential enquiries into Maternal Deaths in the United Kingdom, 1991–1993*. London: Her Majesty's Stationery Office, 1996.
- 234 Nomori H, Horio H, Suemasu K. Pressure-controlled ventilation via a minitracheostomy tube: experimental study using a mechanical lung model. *Surgery Today* 2001; **31**: 780–4.
- 235 Craven RM, Vanner RG. Ventilation of a model lung through various cricothyrotomy devices. *Anaesthesia* 2003; **58**: 507–8.
- 236 Walls R. The emperor's new airway. *Journal of Emergency Medicine* 1992; **10**: 489–90.
- 237 Dworkin R, Benumof JL, Benumof R, Karagianes TG. The effective tracheal diameter that causes air trapping during jet ventilation. *Journal of Cardiothoracic Anesthesia* 1990; **4**: 731–6.
- 238 Smith RB, Schaer WB, Pfaeffle H. Percutaneous transtracheal ventilation for anaesthesia and resuscitation: a review and report of complications. *Canadian Anaesthetists Society Journal* 1975; **22**: 607–12.
- 239 Biro P, Shahinian H. Management of difficult intubation caused by lingual tonsillar hyperplasia. *Anesthesia and Analgesia* 1994; **79**: 389.
- 240 Pavlin EG. Failed intubation. *Canadian Journal of Anaesthesia* 1990; **37**: 706.
- 241 Patel RG. Percutaneous transtracheal jet ventilation. a safe, quick, and temporary way to provide oxygenation and ventilation when conventional methods are unsuccessful. *Chest* 1999; **116**: 1689–94.
- 242 Parmet JL, Colonna-Romano P, Horrow JC, Miller F, Gonzales J, Rosenberg H. The laryngeal mask airway reliably provides rescue ventilation in cases of unanticipated difficult tracheal intubation along with difficult mask ventilation. *Anesthesia and Analgesia* 1998; **87**: 661–5.
- 243 Swartzman S, Wilson MA, Hoff BH, Bunegin L, Smith RB, Sjostrand U. Percutaneous transtracheal jet ventilation for cardiopulmonary resuscitation: evaluation of a new jet ventilator. *Critical Care Medicine* 1984; **12**: 8–13.
- 244 Sdrales L, Benumof JL. Prevention of kinking of a percutaneous transtracheal intravenous catheter. *Anesthesiology* 1995; **82**: 288–91.
- 245 Metz S, Parmet JL, Levitt JD. Failed emergency transtracheal ventilation through a 14-gauge intravenous catheter. *Journal of Clinical Anesthesia* 1996; **8**: 58–62.
- 246 Benumof JL. Transtracheal jet ventilation via percutaneous catheter and high-pressure source. In: Benumof JL, ed. *Airway Management. Principles and Practice*. St. Louis: Mosby, 1996: 455–74.
- 247 Stewart RD. Manual translaryngeal jet ventilation. *Emergency Medical Clinics of North America* 1989; **7**: 155–64.

- 248 Meyer PD. Emergency transtracheal jet ventilation system. *Anesthesiology* 1990; **73**: 787–8.
- 249 Gaughan SD, Benumof JL, Ozaki GT. Can an anesthesia machine flush valve provide for effective jet ventilation? *Anesthesia and Analgesia* 1993; **76**: 800–8.
- 250 Dunlap LB, Oregon E. A modified, simple device for the emergency administration of percutaneous transtracheal ventilation. *JACEP* 1978; **7**: 42–6.
- 251 Egol A, Culpepper JA, Snyder JV. Barotrauma and hypotension resulting from jet ventilation in critically ill patients. *Chest* 1985; **88**: 98–102.
- 252 Benumof JL, Gaughan SD. Concerns regarding barotrauma during jet ventilation. *Anesthesiology* 1992; **76**: 1072–3.
- 253 Boulton TB. A simple connector for cricothyroid cannulation. *Anaesthesia* 1982; **37**: 221.
- 254 Morley D, Thorpe CM. Apparatus for emergency transtracheal ventilation. *Anaesthesia and Intensive Care* 1997; **25**: 675–8.
- 255 Vanner R. Emergency cricothyroidotomy. *Current Anaesthesia and Intensive Care* 2001; **12**: 238–43.
- 256 Randell T, Soderholm AL, Lindqvist C. Is nasotracheal intubation safe in surgery for mandibular cancer? *Archives of Otolaryngology – Head and Neck Surgery* 1992; **118**: 725–8.
- 257 Johnson C. Fiberoptic intubation prevents a tracheostomy in a trauma victim. *AANA J* 1993; **61**: 347–8.
- 258 Fundingsland BW, Benumof JL. Difficulty using a laryngeal mask airway in a patient with lingual tonsillar hyperplasia. *Anesthesiology* 1996; **84**: 1265–6.
- 259 Davies S, Ananthanarayan C, Castro C. Asymptomatic lingual tonsillar hypertrophy and difficult airway management: a report of three cases. *Canadian Journal of Anaesthesia* 2001; **48**: 1020–4.
- 260 Hagberg CA. Current concepts in the management of the difficult airway. In: Schwartz AJ, Matjasko MJ, Otto CW, eds. *ASA Refresher Courses in Anesthesiology*, Vol. 29. Philadelphia: Lippincott; Williams & Wilkins, 2001: 135–46.
- 261 Milner SM, Bennett JD. Emergency cricothyrotomy. *Journal of Laryngology and Otolaryngology* 1991; **105**: 883–5.
- 262 Erlandson MJ, Clinton JE, Ruiz E, Cohen J. Cricothyrotomy in the emergency department revisited. *Journal of Emergency Medicine* 1989; **7**: 115–8.
- 263 Hardy R. Needle tracheostomy for acute upper airway obstruction. *British Medical Journal* 1978; **1**: 854–5.
- 264 Salvino CK, Dries D, Gamelli R, Murphy-Macabobby M, Marshall W. Emergency cricothyroidotomy in trauma victims. *Journal of Trauma* 1993; **34**: 503–5.
- 265 Hawkins ML, Shapiro MB, Cue JI, Wiggins SS. Emergency cricothyrotomy: a reassessment. *American Surgeon* 1995; **61**: 52–5.
- 266 Isaacs JH Jr, Pedersen AD. Emergency cricothyroidotomy. *American Surgeon* 1997; **63**: 346–9.
- 267 Gerich TG, Schmidt U, Hubrich V, Lobenhoffer HP, Tscherne H. Prehospital airway management in the acutely injured patient: the role of surgical cricothyrotomy revisited. *Journal of Trauma* 1998; **45**: 312–4.
- 268 Brofeldt BT, Panacek EA, Richards JR. An easy cricothyrotomy approach: the rapid four-step technique. *Academic Emergency Medicine* 1996; **3**: 1060–3.
- 269 Holmes JF, Panacek EA, Sakles JC, Brofeldt BT. Comparison of 2 cricothyrotomy techniques: standard method versus rapid 4-step technique. *Annals of Emergency Medicine* 1998; **32**: 442–6.
- 270 Davis DP, Bramwell KJ, Hamilton RS, Chan TC, Vilke GM. Safety and efficacy of the Rapid Four-Step Technique for cricothyrotomy using a Bair Claw. *Journal of Emergency Medicine* 2000; **19**: 125–9.
- 271 Engoren M, de St. Victor P. Tension pneumothorax and contralateral presumed pneumothorax from endobronchial intubation via cricothyroidotomy. *Chest* 2000; **118**: 1833–5.
- 272 Morris A, Lockey D, Coats T. Fat necks: modification of a standard surgical airway protocol in the pre-hospital environmental. *Resuscitation* 1997; **35**: 253–4.
- 273 Brantigan CO, Grow JB Sr. Cricothyroidotomy: elective use in respiratory problems requiring tracheotomy. *Journal of Thoracic and Cardiovascular Surgery* 1976; **71**: 72–81.
- 274 Pelausa EO. Percutaneous tracheostomy: ready or not? *Journal of Otolaryngology* 1991; **20**: 88–92.
- 275 Ciaglia P, Brady C, Graniero KD. Emergency percutaneous dilatational cricothyroidostomy: use of modified nasal speculum. *American Journal of Emergency Medicine* 1992; **10**: 152–5.
- 276 Davis DP, Bramwell KJ, Vilke GM, Cardall TY, Yoshida E, Rosen P. Cricothyrotomy technique: standard versus the Rapid Four-Step Technique. *Journal of Emergency Medicine* 1999; **17**: 17–21.
- 277 Bramwell KJ, Davis DP, Cardall TV, Yoshida E, Vilke GM, Rosen P. Use of the Trousseau dilator in cricothyrotomy. *Journal of Emergency Medicine* 1999; **17**: 433–6.
- 278 Chan TC, Vilke GM, Bramwell KJ, Davis DP, Hamilton RS, Rosen P. Comparison of wire-guided cricothyrotomy versus standard surgical cricothyrotomy technique. *Journal of Emergency Medicine* 1999; **17**: 957–62.
- 279 Johnson DR, Dunlap A, McFeeley P, Gaffney J, Busick B. Cricothyrotomy performed by prehospital personnel: a comparison of two techniques in a human cadaver model. *American Journal of Emergency Medicine* 1993; **11**: 207–9.
- 280 Eisenburger P, Laczika K, List M, et al. Comparison of conventional surgical versus Seldinger technique emergency cricothyrotomy performed by inexperienced clinicians. *Anesthesiology* 2000; **92**: 687–90.
- 281 Wong DT, Prabhu AJ, Coloma M, Imasogie N, Chung FF. What is the minimum training required for successful cricothyroidotomy. *Anesthesiology* 2003; **98**: 349–53.
- 282 Schillaci RF, Iacovoni VE, Conte RS. Transtracheal aspiration complicated by fatal endotracheal hemorrhage. *New England Journal of Medicine* 1976; **295**: 488–90.
- 283 Ala-Kokko TI, Kyllonen M, Nuutinen L. Management of upper airway obstruction using a Seldinger minitracheotomy kit. *Acta Anaesthesiologica Scandinavica* 1996; **40**: 385–8.

- 284 Roche N, Durieux P. Clinical practice guidelines: from methodological to practical issues. *Intensive Care Medicine* 1994; **20**: 593–601.
- 285 Cook DJ, Greengold NL, Ellrodt AG, Weingarten SR. The relation between systematic reviews and practice guidelines. *Annals of International Medicine* 1997; **127**: 210–6.
- 286 Woolf SH, Grol R, Hutchinson A, Eccles M, Grimshaw J. Clinical guidelines: potential benefits, limitations, and harms of clinical guidelines. *British Medical Journal* 1999; **318**: 527–30.
- 287 Sigurdsson GH, McAteer E. Morbidity and mortality associated with anaesthesia. *Acta Anaesthesiologica Scandinavica* 1996; **40**: 1057–63.
- 288 Armitage M, Flanagan D. Improving quality measures in the emergency services. *Journal of The Royal Society of Medicine* 2001; **94** (Suppl.): 12.
- 289 Thomas RD, Waites JH, Hubbard WN, Wicks M. Cardiopulmonary resuscitation in a district general hospital: increased success over 7 years. *Archives of Emergency Medicine* 1990; **7**: 200–5.
- 290 McGowan J, Graham CA, Gordon MW. Appointment of a Resuscitation Training Officer is associated with improved survival from in-hospital ventricular fibrillation/ventricular tachycardia cardiac arrest. *Resuscitation* 1999; **41**: 169–73.
- 291 Avarguès P, Cros AM, Daucourt V, Michel P, Maurette P. Procédures utilisées par les anesthésistes-réanimateurs français en cas d'intubation difficile de la conférence d'experts. *Annales Françaises D'Anesthésie et de Réanimation* 1999; **18**: 719–24.
- 292 Svensson E, Angelborg-Thanderz M, Sjoberg L. Mission challenge, mental workload and performance in military aviation. *Aviation Space and Environmental Medicine* 1993; **64**: 985–91.
- 293 Morgan-Jones D, Hodgetts TJ. A unified emergency care system for the early management of emergencies in medicine. *Journal of the Royal Army Medical Corps* 1999; **145**: 61–8.
- 294 Hodgetts TJ, Hanlan CG, Newey CG. Battlefield First Aid: a simple, systematic approach for every soldier. *Journal of the Royal Army Medical Corps* 1999; **145**: 55–9.
- 295 Craig SC, Lee T. Attention to detail: injuries at altitude among U.S. Army Military static line parachutists. *Military Medicine* 2000; **165**: 268–71.
- 296 Freeman KM, Thompson SF, Allely EB, Sobel AL, Stansfield SA, Pugh WM. A virtual reality patient simulation system for teaching emergency response skills to U.S. Navy medical providers. *Prehospital and Disaster Medicine* 2001; **16**: 3–8.
- 297 Butler FK Jr. Tactical medicine training for SEAL mission commanders. *Military Medicine* 2001; **166**: 625–31.
- 298 Connolly TJ, Blackwell BB, Lester LF. A simulator-based approach to training in aeronautical decision making. *Aviation Space and Environmental Medicine* 1989; **60**: 50–2.
- 299 Westrum R. Human factors experts beginning to focus on organizational factors in safety. *ICAO J* 1996; **51**: 6–8.
- 300 Helmreich RL. On error management: lessons from aviation. *British Medical Journal* 2000; **320**: 781–5.
- 301 Allnutt MF. Human factors in accidents. *British Journal of Anaesthesia* 1987; **59**: 856–64.
- 302 Lyons G. Failed intubation. Six years' experience in a teaching maternity unit. *Anaesthesia* 1985; **40**: 759–62.
- 303 Hawthorne L, Wilson R, Lyons G, Dresner M. Failed intubation revisited: 17-yr experience in a teaching maternity unit. *British Journal of Anaesthesia* 1996; **76**: 680–4.
- 304 Rosen M. Difficult and failed intubation on obstetrics. In: Latto IP, Rosen M, eds. *Difficulties in Tracheal Intubation*. London: Ballière-Tindall, 1987: 152–5.
- 305 McBrien ME. Failed tracheal intubation. *British Journal of Anaesthesia* 1996; **77**: 559.
- 306 Dean VS, Jurai SA, Naraynsingh GV, Serrao C. Failed intubation drill. *British Journal of Anaesthesia* 1997; **78**: 231.
- 307 Kessell G. Failed tracheal intubation. *British Journal of Anaesthesia* 1996; **77**: 560.
- 308 Harmer M. Difficult and failed intubation in obstetrics. *International Journal of Obstetric Anesthesia* 1997; **6**: 25–31.
- 309 Rosenstock C, Moller J, Hauberg A. Complaints related to respiratory events in anaesthesia and intensive care medicine from 1994 to 1998 in Denmark. *Acta Anaesthesiologica Scandinavica* 2001; **45**: 53–8.
- 310 Nolan TW. System changes to improve patient safety. *British Medical Journal* 2000; **320**: 771–3.
- 311 Shekelle PG, Woolf SH, Eccles M, Grimshaw J. Clinical guidelines: developing guidelines. *British Medical Journal* 1999; **318**: 593–6.
- 312 Mason RA. Education and training in airway management. *British Journal of Anaesthesia* 1998; **81**: 305–7.
- 313 Stringer KR, Bajenov S, Yentis SM. Training in airway management. *Anaesthesia* 2002; **57**: 967–83.
- 314 Weiss KB. Practice guidelines for practicing doctors. *Journal of General International Medicine* 1998; **13**: 714–5.